ORTHOPAEDICS (15 HRS)

MAIN OBJECTIVE/PURPOSE

The purpose of this course is to enable the learner to acquire knowledge, skills & attitudes in order to promote health, diagnose, manage & coordinate rehabilitation of infants, children & adults suffering from common orthopedic conditions.

ORTHOPAEDICS (15 HRS)

LEARNING OBJECTIVES

Upon completion of this course, the learner should be able to:

1. Recall anatomy & physiology of the skeletal muscular system
2. Describe the process of bone healing
3. Describe common orthopaedic diseases/conditions
4. Demonstrate the ability to share health messages with a patient following application of POP.
5. Demonstrate to a patient how to position the leg following application of skeletal traction

ANATOMY & PHYSIOLOGY

Individual assignment.

Revise the A & P of musculoskeletal system.

Bone healing

Also connective tissue

TALIPES (CLUB FOOT)

TALIPES/ CLUB FOOT

Is a congenitally inverted foot in which adduction, plantar flexion & inversion of the foot occur in varying degrees of severity.

The unilateral form occur commonly than the bilateral form.

RISK FACTORS

1. Intrauterine compression –faulty posture of the fetus in the uterus
2. Decreased growth of distal tibia
3. Family history of talipes
4. Poor muscular development-poor muscles allow the bone to dislocate.

TALIPES

DIAGNOSIS

Clinical manifestation

TREATMENT/MEDICAL MANAGEMENT

Treatment is began immediately & most often requires three stages for correction.

(a) Correction of deformity: Casts are applied in series for gradual stretching & strengthening;

Massages accompanied by special bandaging may be used.

TALIPES/ CLUB FOOT

(b) Maintainance of correction: Orthopaedic shoes.

(c) Follow-up observations to prevent recurrence of the deformity.

NURSING INTERVENTION

1. To assist parents to understand mechanism of treatment to achieve correction.

(a) Appropriate care of cast or brace at home

TALIPES

(b) Follow-up care & importance of frequent cast changes.

2. To facilitate developmental progress & adapt nurturing activities.

(a) Provide appropriate stimuli & activity for developmental level.

(b) Encourage parents to hold & cuddle the baby.

(c) Maintain normal home routine.

TALIPES

COMPLICATIONS

- Pressure sores due to tight casts.
- Rocker bottom deformity of the foot
- Failure to achieve correction.

OSTEOGENESIS IMPERFECTA

OSTEOGENESIS IMPERFECTA

- Also called brittle bone disease.
- Is a defect in the production of collagen resulting in repeated fractures with minor trauma.
- Spontaneous fractures occur in utero (osteogenesis congenita) or during birth or childhood (osteogenesis imperfecta tarda)
- Healing of the bone fractures progresses normally.

OSTEOGENESIS IMPERFECTA

- Later in life the tendency to fracture decrease & often disappears.
- Vast majority of cases are transmitted as autosomal dorminant traits although a small percentage of congenital cases are transmitted as autosomal recessive

OSTEOGENESIS IMPERFECTA

PRESENTATION

1. Trauma during delivery may lead to intracranial hemorrhage & stillbirth.
2. At birth the skull is soft & feels like a “bag of bones”.
3. Infants born alive may die suddenly during the first few days or week.
4. Survivors develop shortened extremities & other bony deformities.

OSTEOGENESIS IMPERFECTA

5. Mental development is normal unless CNS injury occurs.
6. The sclerae is thin, translucent & appear blue.
7. Hearing loss from otosclerosis may occur.
8. Joint instability.

OSTEOGENESIS IMPERFECTA

MANAGEMENT

- To prevent fractures & increase function
- Orthopedic treatment
- Physiotherapy & occupational therapy
- Treatment with biphosphonate pamidronate given iv has been shown to increase bone mineral density & motor function & may decrease bone pain & resorption.

OSTEOGENESIS IMPERFECTA

COMPLICATION

1. Failure to gain weight
2. Bone deformities & dwarfism

HIP DYSPLASIA

- Is a malformation of the hip as a result of imperfect development of the femoral head or the acetabulum or both.
- The structures that support the hip joint & holds the joint together are too loose, or the joint cavity is too shallow.

RISK FACTORS

1. Frequently associated with other congenital deformities.
2. Prenatal factors e.g. maternal hormonal secretion, intrauterine posture especially frank breech position

HIP DYSPLASIA

CLINICAL MANIFESTATIONS (NEWBORN)

1. Ortolani’s sign: Infant supine, knees flexed, hips fully abducted, a click is heard or felt as the hip is reduced by the abduction.
2. Asymmetrical gluteal & thigh folds.
3. Shortening of the leg on the affected side, one knee is lower than the other (Galeazzi sign)

HIP DYSPLASIA

DIAGNOSIS

- X-ray film
- CT Scan

TREATMENT

- Is initiated as soon as condition is identified
- For newborn, the dislocated hip is securely held in a full abduction position. This keeps the femur in the acetabulum & stabilizes the area

HIP DYSPLASIA

- Abduction devices

a) Pavlik harness: a fabric, strap harness that is secured around the infant’s shoulders & chest & is connected to straps around the lower leg. The harness maintains the legs in a flexed, abducted position at the hip. The harness maybe removed for bathing, but the infant will wear it full time until the hip is stable.

HIP DYSPLASIA

b) Hip spica cast, most often used when adduction contracture is present. After the removal of the cast, a protective abduction brace is fitted.

c) Closed reduction: Performed in older children, 6-8 months old.

d) Open reduction: becomes increasingly difficult after the age of 4 years.

HIP DYSPLASIA-PAVLIK HARNESS

HIP DYSPLASIA

NURSING INTERVENTION

1. To identify hip dysplasia in the newborn before discharge.
2. To assist parents to understand mechanisms to maintain reduction

(a) Pavlik brace: Teach parents the application of brace, undershirts should be worn beneath the brace. Check skin under brace for irritation or pressure areas, no lotions or oils should be applied to the skin that will be under brace.

HIP DYSPLASIA

(b) Teach parents cast care if hip spica cast is applied.

3. To facilitate developmental progress.

a) Provide appropriate stimuli & activity for developmental level.

b) Encourage parents to hold & cuddle child.

c) Maintain normal home routine.

OSTEOPOROSIS (POROUS BONE)

OSTEOPOROSIS (POROUS BONE)

- A metabolic bone disease that involves an imbalance between new bone formation & bone resorption.
- Primary osteoporosis is the most common type, often in women after menopause because low levels of estrogen are associated with an increase in bone resorption.
- Bone loss occurs predominantly in the vertebral bodies of the spine, femoral neck in the hip, & the distal radius of the arm. Bone mass declines, leaving the bones brittle & weak.

OSTEOPOROSIS (POROUS BONE)

RISK FACTORS

1. Increased incidence in women after the age of 50 yrs.
2. Early menopouse
3. Low peak bone mass (maximum amount of bone a person achieves)
4. Excessive alcohol intake-act on bone cells to reduce remodeling by increasing the parathyroid hormone
5. Sedentary lifestyle

N/B OESTROGEN MAINTAINS BONE MASS IN ADULT WOMEN

OSTEOPOROSIS

6. Endocrine disorders of the thyroid & parathyroid glands.
7. Eating disorders
8. Cigarette smoking
9. Insufficient dietary calcium
10. Long term use of corticosteroids (decreases collagen synthesis & increase collagen breakdown).

OSTEOPOROSIS

CLINICAL MANIFESTATIONS

1. Maybe asymptomatic until x-ray films demonstrate skeletal weakening.
2. Spinal deformity & dowager’s hump resulting from repeated pathological, spinal vertebral fractures.
3. Spinal fractures may occur spontaneously or as a result of minimal trauma.

OSTEOPOROSIS

4. Chronic low thoracic & midline back pain
5. Height loss may precipitate thoracic problems, decrease in abdominal capacity, & decrease in exercise tolerance.
6. Hip fractures & vertebral column collapse are the most debilitating problems.

DIAGNOSTICS

1. Serum calcium, phosphorus, & alkaline phosphatase & PTH are usually normal

OSTEOPORISIS

2. CT Scan or bone density scan to evaluate bone loss.

MEDICAL MANAGEMENT

1. Medications: calcium supplements, vit. D supplements, estrogen replacement therapy & medications that facilitate increased bone density.
2. Dietary: increased intake of protein, calcium & vit. D.

OSTEOPOROSIS

3. Exercise: activities that put moderate stress on bones working them against gravity (walking, racquet sports, jogging).
4. Compression fractures of the vertebrae usually heal with surgical intervention.

NURSING INTERVENTION

1. pain relief; bedrest; firm mattress & narcotic analgesic initially, followed by non steroidal antiinflammatory drugs.

OSTEOPOROSIS

2. Assess bowel & bladder function, patient will be prone to constipation & paralytic ileus if vertebrae are involved.
3. Regular daily exercise; encourage outdoor exercise (to increase the utilization of vit. D)
4. Increased calcium intake & estrogen therapy.
5. Education:-decrease falls & injury by maintaining safe home environment

OSTEOPOROSIS

- understand the need to continue taking medication even if they do not make the patient feel better, they prevent further damage.
- do not exercise if pain occurs.
- avoid heavy lifting, stooping & bending. Review & demonstrate good body mechanics with the client.

OSTEOPOROSIS

PREVENTION

1. Diet adequate in protein, calories, calcium & vit. D.
2. Calcium & vit. D supplements & exercise for those at risk.
3. Consider hormonal replacement for hypogonadal men & women.
4. Consider biphosphate if pt is on corticosteroids for more than 2 weeks & for prevention of osteoporosis.

OSTEOPOROSIS

5. Give calcium supplement with meals to reduce risk of calcium oxalate nephrolithiasis.

COMPLICATION

Bone fracture occurring in the vertebral bodies, distal radius or hip.

BONE TUMOR-BONE CYST

BONE TUMOURS

TUMOR-abnormal swelling due to rapid growth of tissue which may be benign or malignant

TYPES

a. Osteogenic- of bone origin
b. Chondronic- of cartilage origin
c. Fibrogenic- from fibrous tissue
d. Rhabdomyogenic- of muscular origin
e. Others are marrow (reticulum), nerve, vascular & fatty cell tumors.

- Could be primary or metastatic tumor.

BONE TUMOURS

BENIGN BONE TUMOURS-

- They do not metastasize to other tissues.Are more common than malignant primary bone tumours.
- Generally are slow growing & well circumscribed, present few symptoms, & are not a cause of death.
- **Examples**:- osteochondroma, bone cyst, fibroma.
- Some benign tumors such as giant cell tumors (osteoclastoma) have the potential of undergoing malignant transformation.

BONE TUMOUR

MALIGNANT BONE TUMOURS

- Primary malignant musculoskeletal tumours are relatively rare & arise from connective & supportive tissue cells (sarcomas) or bone marrow elements (myelomas).
- Malignant primary musculoskeletal tumours include osteosarcoma, chondrosarcoma, Ewing’s sarcoma & fibrosarcoma.

BONE TUMOURS

- Soft tissue sarcomas include liposarcoma, fibrosarcoma.
- Osteogenic sarcoma (osteosarcoma) is the most common & most often fatal malignant bone tumour. The tumour carries a high mortality rate because the sarcoma often has spread to the lungs by the time pt seeks healthcare. Long bone is often affected.

BONE TUMOURS

METASTATIC BONE DISEASE

- More common than any primary bone tumour.
- From elsewhere the most common primary sites of tumors that metastasize to bone include the kidney, prostate, lung, breast, ovary & thyroid.

BONE TUMOURS

RISK FACTORS

1. Male between 10-25 years
2. Older people with paget’s disease
3. A result of radiation exposure

PATHOPHYSIOLOGY

A tumour causes normal bone tissue to react by osteolytic response (bone destruction) or osteoblastic response (bone formation). Primary tumours cause bone destruction, which

BONE TUMOURS

Weakens the bone, resulting in bone fractures. The bones surface changes & the contour enlarges in the tumor area.

Malignant bone tumors spreads in blood along the walls of the veins. This invade & destroy adjacent bone tissue & benign bone tumors place pressure on adjacent bone tissue. This weakens the structure of the bone until it can no longer withstand the stress of ordinary use. Pathologic fractures commonly result.

BONE TUMOURS

CLINICAL MANIFESTATION

1. Varying degrees of disability
2. Weight loss
3. Malaise
4. Fever
5. Spinal cord compression (spinal metastasis)
6. Palpable, tender, & fixed bone mass.

BONE TUMOURS

DIAGNOSTICS

1. History & physical examination
2. Diagnostic studies: CT Scan, bone scan, myelogram, arteriography, MRI, biopsy, & CXR.

TREATMENT

I. Amputation of extremity &/or extensive surgical resection of bone & surrounding tissue.

BONE TUMOURS

2. Chemotherapy
3. Radiotherapy

NURSING INTERVENTION (post excision of tumor)

1. Pain relieve: pharmacologic & non-pharmacologic pain mx. Work with pt for effective pain mx regime increasing pt control.

BONE TUMOURS

2. Wound care as healing maybe delayed because of surgery & radiotherapy. Minimize pressure on wound.
3. Adequate nutrition, address anorexia, nausea & vomiting post chemotherapy & radiotherapy.
4. Prevent wound infection- antibiotics & aseptic wound dressing techniques. If pt is on chemotherapy monitor WBC.

BONE TUMOUR

5. Give psychological care.
6. physiotherapy.
7. Teach on meds, dressing, treatment regimen, physical & occupational therapy programs, & complications.

SKELETAL TUBERCULOSIS

- It is caused by dissemination of bacilli via the blood stream early in the course of the initial infection.
- In some cases spread to bone appears to result from lymphatic drainage from another infected area such as the pleura or kidney.
- May smolder for years before being discovered.

SKELETAL TUBERCULOSIS

- Basic lesions almost always is a combination of osteomyelitis & athritis.
- In adults, skeletal tuberculosis usually occurs in weight- bearing joints; spine, hip & knees.

PATHOPHYSIOLOGY

- An inflammatory reaction is followed by formation of granulation tissue that begins to erode & destroy cartilage & eventually cancellous bone, ultimately leading to demineralization &

SKELETAL TUBERCULOSIS

Necrosis. The healing process involves deposition of fibrous tissue.

PRESENTATION

1. Multiple osteolytic lesions.
2. Pain
3. Slight narrowing of vertebral space.
4. Later vertebral body destruction with collapse & formation of kyphosis & scoliosis

SKELETAL TUBERCULOSIS

POTT'S DISEASE (TUBERCULOSIS SPONDULOSIS)

- This is TB of the spine.
- Half of the cases of skeletal tuberculosis occur in the spine.
- Infectious process begins in the anterior part of a vertebral body.
- The disk space between two involved vertebrae is usually destroyed, producing the characteristic anterior wedging of two involved vertebrae with loss of intervening disk space.

SKELETAL TUBERCULOSIS

- The resulting deformity may produce a characteristic posterior prominence of the spine
- Thoracic spine is involved most frequently
- Lumber spine is next, & cervical & sacral spines least often.

POTT'S ABSCESS & SINUS FORMATION

- Pus from a vertebral focus ruptures anteriorly, enveloping the spine & producing a paraspinal abscess

SKELETAL TUBERCULOSIS

- Since it is confined by tight ligamentous investments, it can develop higher pressure, dissect along tissue planes for long distance, & present as a mass in the supraclavicular space, above the posterior iliac crest in the petit’s triangle the groin, the buttock, or even the popliteal fossa.
- Cases of Pott’s abcess perforating into the bowel have been reported, resulting in a gas-filled psoas

SKELETAL TUBERCULOSIS

visible on x-ray films.

- Rupture into adjacent lung has been observed.
- The abscess can spread infection to other vertebral bodies, sometimes with intervening normal spine.

POTT'S PARAPLEGIA

- Paralysis of lower extremities can develop in several ways.

SKELETAL TUBERCULOSIS

- Pressure in a paraspinal abscess can produce ischemic changes in the subjacent cord.
- In such cases neurologic symptoms are promptly relieved by drainage of the abscess.
- Caseous or granulating tissue may extrude from the posterior aspect of the vertebral body & impinge on the anterior aspect of the cord.
- Inflammatory thrombosis of the anterior spine artery can occur.

SKELETAL TUBERCULOSIS

- Sudden cord transections(injury) may result from serious loss of structural integrity.

INVESTIGATIONS

1. Tuberculin test: precise intracutaneous injection producing a raised, blanched wheal. The reaction is read in 48-72 hrs, a positive test defined as greater than 10mm of induration.

SKELETAL TUBERCULOSIS

2. Tissue or pus culture & specify of micro-organism.
3. CT spine, MRI, x-ray

TREATMENT

1. Bed rest to relief pain
2. Drainage or debridement of large paraspinal abscesses if they are causing paraplegia or paraparesis

SKELETAL TUBERCULOSIS

3. Prolonged treatment (2 years) with an INH (isoniazid)- containing regimen is indicated & many advise including RMP (rifampicin) for 9 months.
4. Advanced neurologic defects & severe anatomic instability of the spine require more radical orthopedic approaches.

ATHRITIC HAND

ARTHRITIC KNEE

ARTHRITIS

- It is the inflammation of a joint, usually accompanied by pain, swelling & changes in structure.
- Occurs in many forms e.g

a. Acute secondary arthritis: arthritis caused by osteitis.
b. Acute suppurative purulent distention of synovial sac: a serious form usually due to bacterial infection.
c. Allergic arthritis: arthritis following ingestion of food allergens or occurring in serum sickness
d. Palindromic arthritis: transient recurrent arthritis, of unknown etiology of the large joints.

ARTHRITIS

ETIOLOGY

1. Infection; gonococcus, tuberculous, pneumococcal.
2. Rheumatic fever
3. Ulcerative colitis
4. Trauma

ARTHRITIS

5. Degerative joint disease e.g. osteoarthritis.
6. Metabolic disturbances such as gout.
7. Neoplasms e.g synovioma.
8. para- or peri-articular conditions eg fibromyositis
9. Psoriasis

ARTHRITIS

SIGNS & SYMPTOMS

Joint inflammation; redness, swelling, pain & reduced mobility

TREATMENT

1. Treat underlying cause.
2. Pts often benefit from referal to occupational or physiotherapy or both.

OSTEOARTHRITIS (O.A)

- Also known as joint degenerative disease or osteoarthrosis.
- It is a progressive nonsystemic, noninflammatory disease that causes a progressive degeneration of synovial joints of weight- bearing long bones.
- OA has been classified as primary (idiopathic, with no prior event or disease related to the AO) or secondary. Distinction is always not clear between primary & secondary OA.

OSTEOARTHRITIS

RISK FACTORS

1. Increased age
2. Genetic predisposition
3. Gender & hormonal factors
4. Obesity
5. Mechanical factors.
6. Prior inflammatory disease

OSTEOARTHRITIS

CLINICAL MANIFESTATIONS

1. Pain, swelling, tenderness
2. Crepitus: a grating sound or feeling with movement.
3. Instability; stiffness & immobility.
4. Pain increases with motion & weight bearing.
5. Herberdens nodes: bony nodules on the distal finger joints.

OSTEOARTHRITIS

DIAGNOSTICS

1. Synovial joint analysis
2. Bone scan
3. X-ray films

TREATMENT

4. Medication to relief pain, NSAIDS eg acetaminophen
5. Activity balanced with adequate rest
6. Weight reduction, if appropriate

OSTEOARTHRITIS

4. Physical therapy & exercise
5. Joint rest & avoidance of joint overuse.
6. Use of orthotic device to support inflamed joints (splints, braces).

NURSING MANAGEMENT

1. Acute inflamed joint should be immobilized with splint or brace.

OSTEOARTHRITIS

2. Plan ADLs to prevent stress on involved joints & promote rest.
3. Heat compresses to relief pain & cold compresses for inflamed joints
4. Maintenance of regular exercise

assignment

- Read and make short notes on
- Rheumatoid arthritis
- Gout arthritis

SCOLIOSIS

Is a lateral S-shaped curvature of the thoracic & lumbar spine.

If allowed to progress without treatment, it will severely affect the shape of the thoracic cavity & impair ventilation.

Could be structural or postural (non-structural).

Structural: classifications are idiopathic, congenital, neuromuscular & syndromic or miscellaneous (infection).

SCOLIOSIS

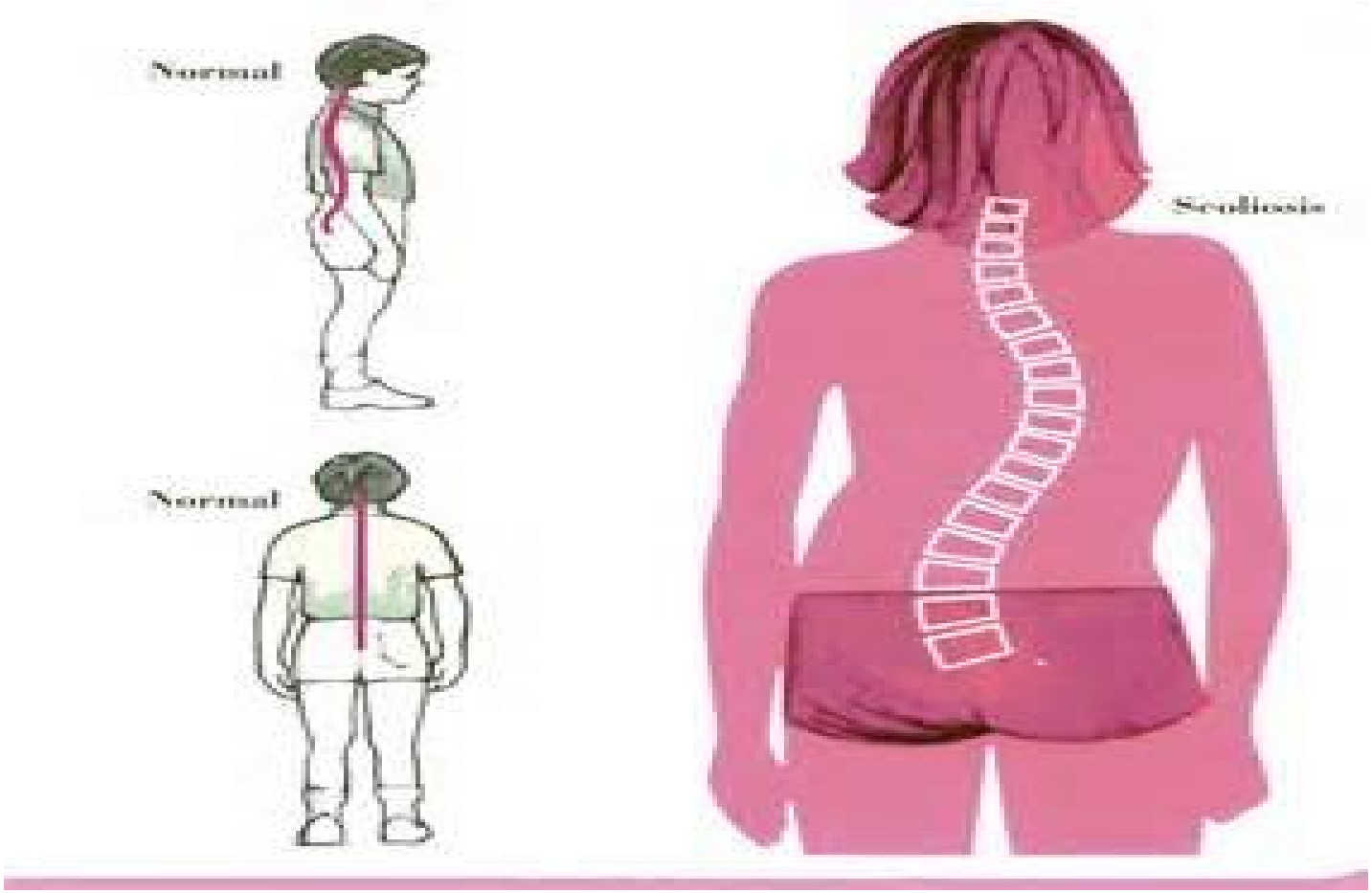

CLINICAL MANIFESTATIONS

a) Uneven hips & shoulders
b) Visible curvature of the spinal column; head & hip are not in alignment.
c) When a child bends forward from the waist, there is visible asymmetry of the shoulders.
d) Waistline is uneven. One hip is more prominent.

DIAGNOSTICS

1. Clinical manifestations
2. X-ray film- AP & lateral spine
3. MRI – especially for those with neurological deficit.
4. Straight-leg-raising test is performed by the nurse on the pt on a supine position & will complain of sciatica or leg pain

TREATMENT

1. Observation & monitoring for curvature less than 20 degrees.
2. Brace if curvature shows progression 20-40 degrees. Maintain the size of deformity.
3. Surgery if the curvature is 40-50 degrees. Spinal fusion & placement of a rod to prevent destruction of the fused segment. The rod may be left in place permanently unless it becomes displaced or causes discomfort.

NURSING INTERVENTION

1. Promote health programs in school to identify condition early.
2. Assist pt & parents to properly use braces.

a) Make sure brace is properly fitted & does not inadventently rub bony prominences.

b) May put light T-shirt under brace for comfort.

c) Initially, the brace is worn 20-23 hrs/day till skeleton mature.

d) Brace is regularly adjusted to promote correction.

e) If progress is good, child is weaned from the brace during the daytime & wears it only at night.

f) Supplemental exercises.

3. Support normal growth & development & to develop a positive self-image.

a) Encourage peer socialization.

b) Encourage independence

c) Encourage child to participate in & be independent in scheduling of activities & other aspects of care.

d) Emphasize positive long-term outcome.

4. Maintain spinal alignment after surgical correction. (care of pt after laminectomy & fusion).

5. Maintain homeostasis & assess for complications after surgical correction.

ANKYLOSING SPONDYLITIS

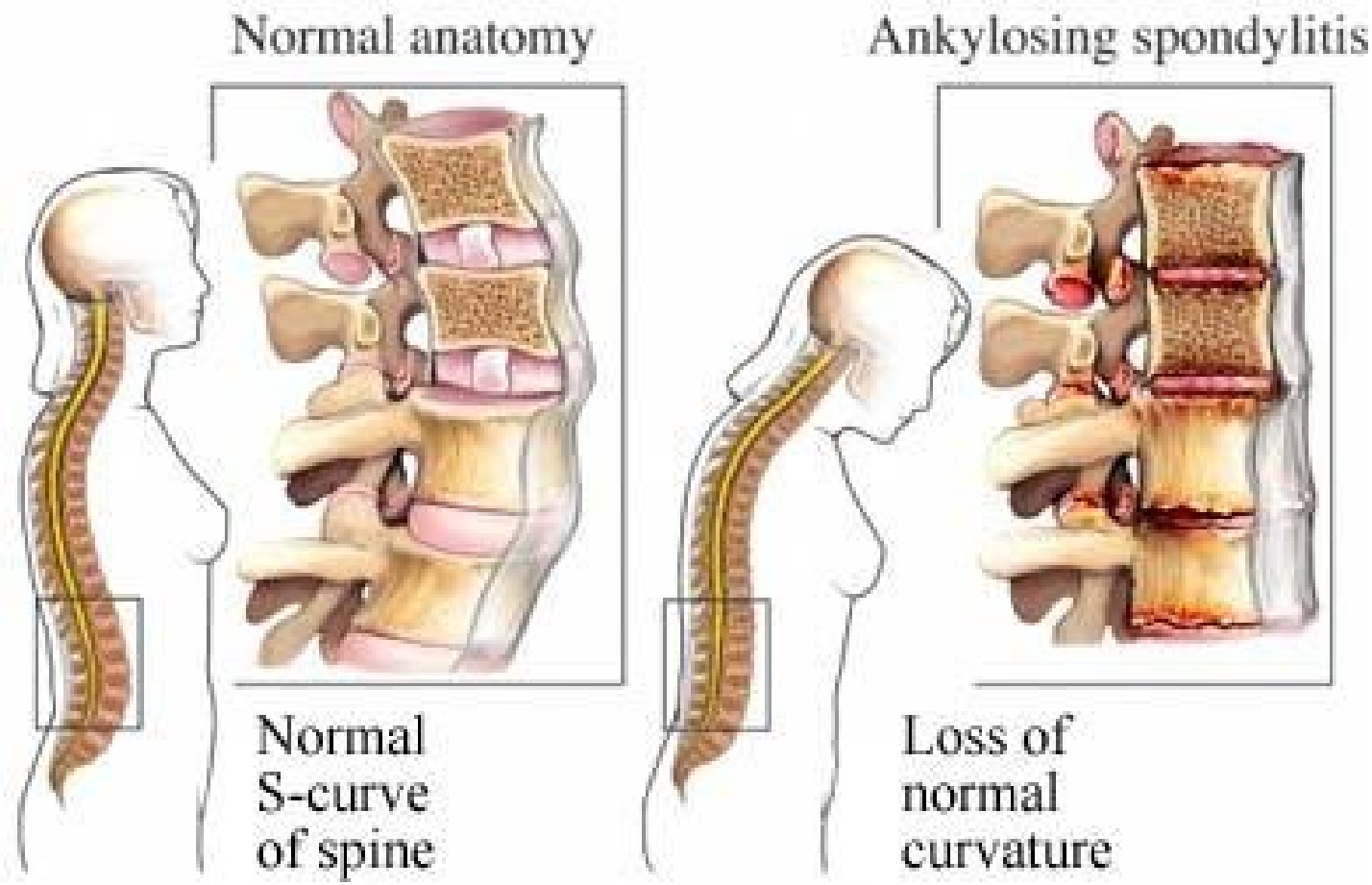

ANKYLOSING SPONDYLITIS

- Ankylosis is fixation or immobility of a joint.
- Ankylosing spondylitis affects the cartilaginous joints of the spine & surrounding tissues. Occasionally, the large synovial joints, such as hips, knees or shoulders, maybe involved.
- It is usually diagnosed in the second or third decade of life.

ANKYLOSING SPONDYLITIS

- The disease is not usually as severe in females as in males, in whom the disease is more prevalent & likely to have significant systemic involvement.

CLINICAL MANIFESTATION

1. Low back pain which improves with exercise.
2. Early morning stiffness or stiffness after immobility.

ANKYLOSING SPONDYLITIS

3. Enthesitis (inflammation at points of insertion of ligaments & tendons) & occurs as heel, plantar or chest pain.

DIAGNOSTICS

Diagnosis is too often delayed by 8-10 yrs because of increased prevalence of back pain in community.

ANKYLOSING SPONDYLITIS

1. ESR & CRP not always elevated, radiographs will be normal in early disease.
2. CT-scan: shows erosive changes
3. MRI enhanced: most sensitive technique to detect joint & lumbar-spine inflammation.

TREATMENT

Regular exercise to maintain ROM by physiotherapy.

Regular follow-up

Increased doses of NSAIDS.

OSTEOMYELITIS

OSTEOMYELITIS

- An infection of the bone, bone marrow & surrounding soft tissue.
- Causation organisms are staph. Aureus (70-80 %), Proteus, psuedomonas & E. Coli.

OSTEOMYELITIS

RISK FACTORS.

1. Indirect entry of organism

a) Hematogenic

b) Injury & infection of adjacent soft tissue.

2. Direct injury to bone:

a) Trauma

b) Surgical procedures.

OSTEOMYELITIS

PATHOPHYSIOLOGY

Inflammatory response occurs initially, with increased vascularization & edema. After 2 or 3 days, thrombosis of the blood vessels occurs resulting in ischemia with bone necrosis. The infection extends into the medullary cavity & under the periosteum & may spread into adjacent soft tissues & joints. Without prompt

OSTEOMYELITIS

treatment bone abscesses form which contains dead bone tissue (**sequestrum**) that does not easily liquify & drain. New bone growth (**involucrum**) forms & surrounds the sequestrum. Although healing appears to take place, achronically infected sequestrum remains & produces recurring abscesses throughout the the pt’s life. This is referred to as chronic osteomyelitis.

OSTEOMYELITIS

CLASSIFICATION

Acute osteomyelitis: sudden onset, may heal in 2 to 3 weeks or progress to chronic status.

Chronic osteomyelitis: a continuous, persistent problem or exacerbation of previous problem.

OSTEOMYELITIS

CLINICAL MANIFESTATION

1. Acute

a) Tenderness, swelling & warmth in affected area.

b) Drainage from infected site.

c) Fever, chills

d) Constant pain in affected area.

e) Circulatory impairment

OSTEOMYELITIS

2. Chronic

a) Drainage from wound or sinus tract
b) Recurrent episodes of bone pain
c) Low grade fever
d) Remission & exacerbation of problem.

OSTEOMYELITIS

DIAGNOSTICS

1. Wound culture, blood culture to identify appropriate antibiotic therapy.
2. Radionuclide bone scan , MRI for early definitive diagnosis.
3. X-ray plate only shows soft tissue swelling till after 2 weeks.
4. Bone or soft tissue biopsy.

OSTEOMYELITIS

TREATMENT

1. Intensive IV antibiotics therapy 3 to 6 weeks.
2. Immobilization of the affected area.
3. Surgical debridement may be necessary with antibiotic beads impregnated i.e sequestrectomy (removal of enough involucrum to enable removal of sequestrum)

OSTEOMYELITIS

NURSING INTERVENTION

1. Administration of antibiotics, analgesics
2. Prevent contractures especially of the affected extremity.
3. Care of open wounds & some pts are isolated
4. Education on drug compliance because they are going to take antibiotics for a long time, infection control measures & keeping follow-up appointments.

OSTEOMYELITIS

PREVENTION

1. Treatment of focal infections diminishes hematogenous spread.
2. Post pone elective orthopedic surgery if pt has recurrent infection e.g UTI, sore throat or history of a recent infection.
3. Prophylactic antibiotics with invasive procedures on pts with joint replacement surgery.

OSTEOMYELITIS

4. Asepsis during orthopedic surgery.
5. Aseptic post op wound care.

CONTUSION

- Is a soft tissue injury produced by blunt force e.g a blow, kick or fall. Many small blood vessels rupture & bleed into soft tissues (ecchymosis/ bruising). A hematoma develops when the bleeding is sufficient to cause an appreciable collection of blood.
- Local symptoms (pain, swelling & discoloration) are controlled with intermittent application of cold.
- Most contusions resolve in 1-2 weeks.

STRAIN

- Is a “muscle pull” from over use, overstretching, or excessive stress.
- Strains are microscopic, incomplete muscle tears with some bleeding into the tissue.
- Patient experiences soreness or sudden pain with local tenderness upon muscle use & isometric contraction

SPRAIN

Inversion sprain
Eversion sprain
Sprained lateral ligament
Sprained medial ligament

SPRAIN

- Is an injury to ligaments surrounding a joint, caused by a wrenching or twisting motion.
- The function of a ligament is to maintain stability while permitting mobility.
- A torn ligament loses stabilizing ability.
- Blood vessels rupture & edema occurs, the joint is tender & movement becomes painful.
- The degree of disability & pain increases during the first 2-3 hrs after the injury because of the associated swelling & bleeding.

SPRAIN

- The patient should have an x-ray to evaluate for bone injury.
- Avulsion fracture (a bone fragment is pulled away by a ligament or tendon) may be associated with a sprain.

TREATMENT (CONTUSION, STRAIN & SPRAIN)

- Resting (prevent further injury & promote healing) & elevating the affected part (control swelling)
- Apply cold (ice) (produces vasoconstriction which reduces bleeding & edema)

Note: acronyme RICE- Rest, Ice, Compression, Elevation.

- Monitor neurovascular status (circulation, motion, sensation).

TREAMENT

- After the first 48 hrs of acute inflammation stage heat may be applied to promote vasodilation, absorption & repair.
- Exercise after 2 or more days depending on the severity of injury.

JOINT DISLOCATION

- Is a condition in which the articulate surfaces of bones forming the joint are no longer in anatomic contact.
- The bones are literally “out of joint”.
- A **subluxation** is a partial dislocation of the articulating surfaces.
- Traumatic dislocations are orthopedic emergency. Otherwise vascular necrosis & nerve palsy may occur.
- Dislocations may be congenital (hip), spontaneous or pathological or traumatic.

JOINT DISLOCATION

SIGNS & SYMPTOMS OF A TRAUMATIC DISLOCATION

1. Pain
2. Change in contour of the joint
3. Change in the length of extremity
4. Loss of normal mobility
5. Change in axis of the dislocated bones.

JOINT DISLOCATION

DIAGNOSIS

- X-ray confirms diagnosis & demonstrates possible associated fractures.

MEDICAL MANAGEMENT

1. Immobilization of the joint while pt is transported to hospital.
2. Prompt reduction to preserve joint function
3. Joint immobilization by bandages, splints, casts or traction.

JOINT DISLOCATION

4. Monitor neurovascular status.
5. After several days to weeks passive & active movement 3-4 times a day is began to preserve ROM. Support joint between the exercise.

NURSING MANAGEMENT

a. Promote comfort, evaluate neurovascular status, & protecting joint during healing.
b. Teach pt to manage immobilizing devices & how to protect joint from injury.

FRACTURES

DEFINITION

- A disruption or break in the continuity of the bone.
- Usually as a result of a traumatic injury

Characteristics of bones in children affecting fracture & fracture healing.

a) Presence of epiphyseal plate; if damaged, may affect the growth of the long bone.
b) Periosteum is thicker & stronger & has an increased blood supply; therefore healing is more rapid.
c) Bones are more porous & allow for greater flexibility.

CLASSIFICATION OF FRACTURES

1. **According to pattern of fracture**
   a) **Complete:** fracture line extends through the entire bone; the periosteum is disrupted on both sides of the bone.
   b) **Incomplete**: fracture line extends only partially through the bone (greenstick, hairline).
   c) **Comminuted**: fracture with multiple bone fragments; more common in adults.
   d) **Impacted:** complete fracture in which bone fragments are driven into each other.

FRACTURES

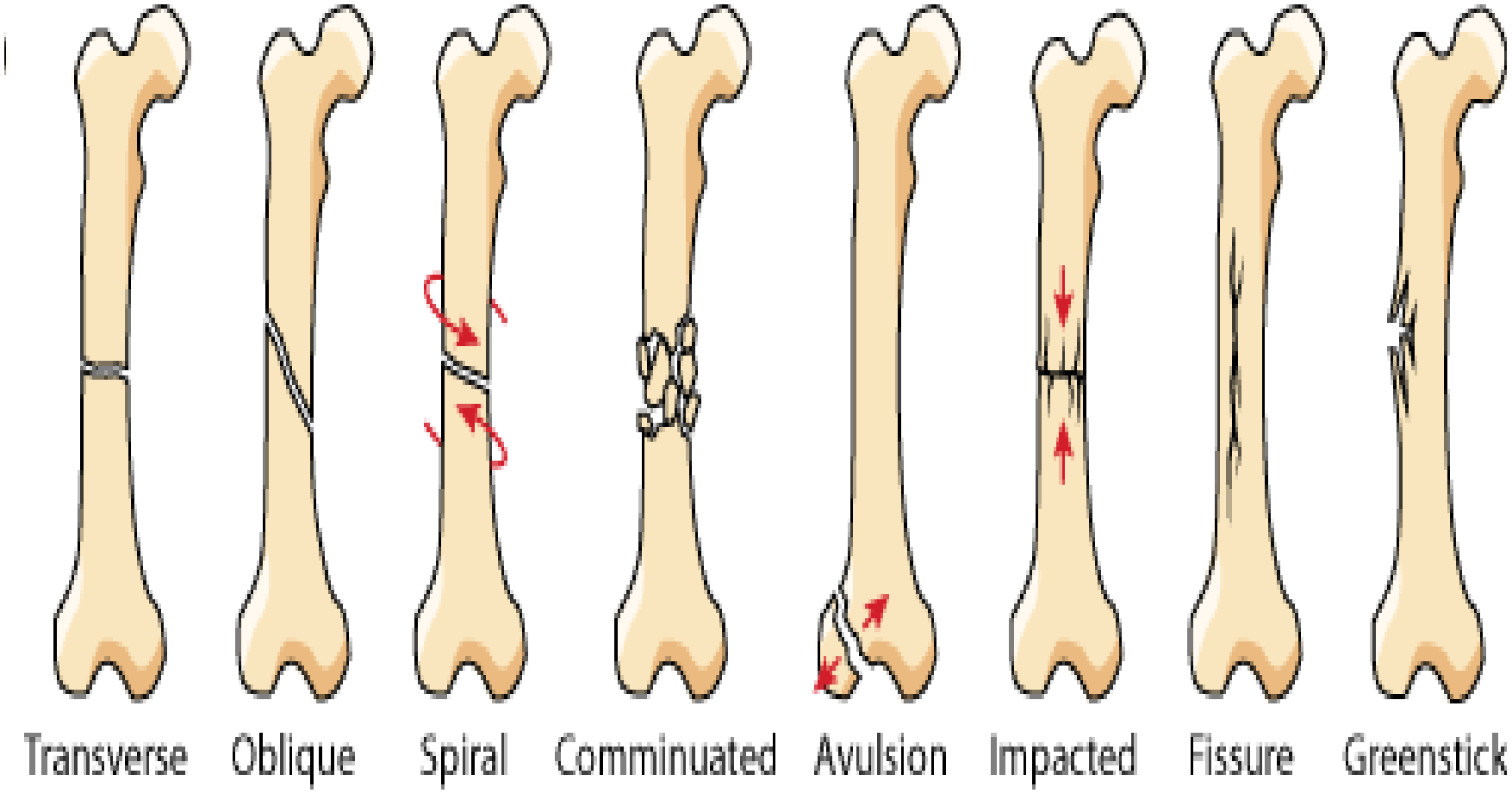
Transverse
Oblique
Spiral
Comminuated
Avulsion
Impacted
Fissure
Greenstick

2. **According to location of the fracture**
   a) Proximal
   b) Middle
   c) Distal
3. **Stable vs Unstable fractures.**
   a) **Stable:** a portion of the periosteum remains intact; frequently transverse, spiral or greenstick fractures.
   b) **Unstable:** bones are displaced at the time of injury, with poor approximation; frequently comminuted or impacted.

4. **Simple vs Complex fractures.**
   a) **Simple, closed fracture**: does not produce a break in the skin.
   b) **Complex, open or compound fracture**: involves an open wound through which the bone has protruded
5. **Anatomic location (colles & potts fractures)**
   a) **Colles':** fracture within the last inch of the distal radius, distal fragment is displaced in a position of dorsal & medial deviation.
   b) **Potts':** fracture of distal fibula, seriously disrupting the tibio-fibular articulation, a piece of medial melleolus may be chipped off as a result of rupture of internal ligaments.

FRACTURE

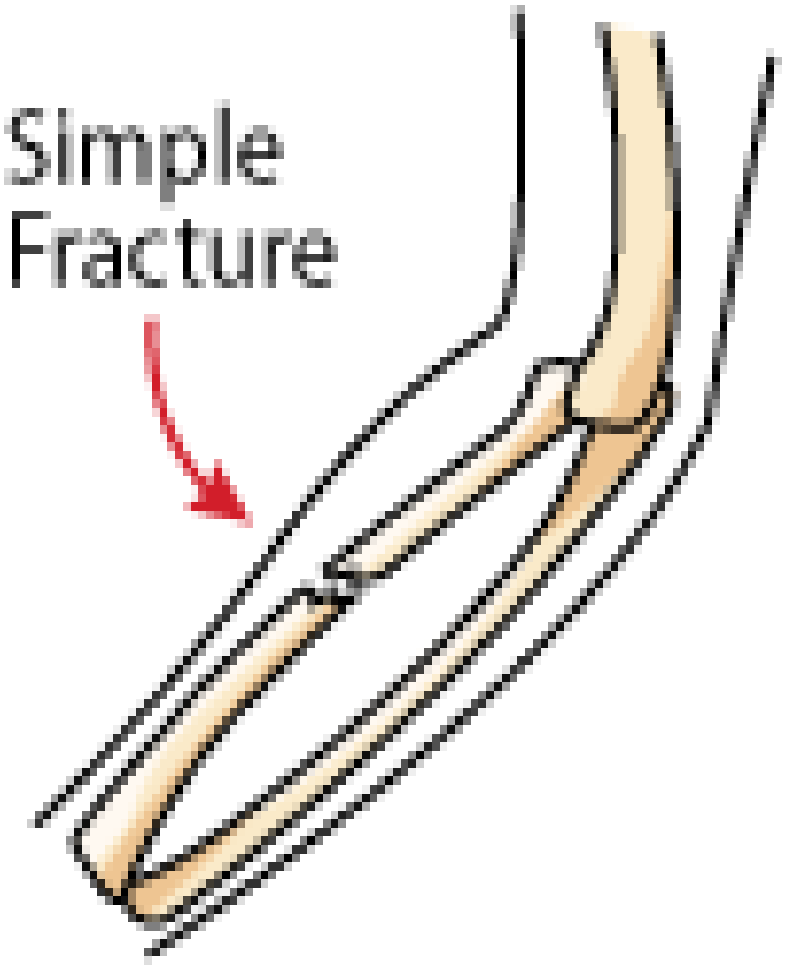

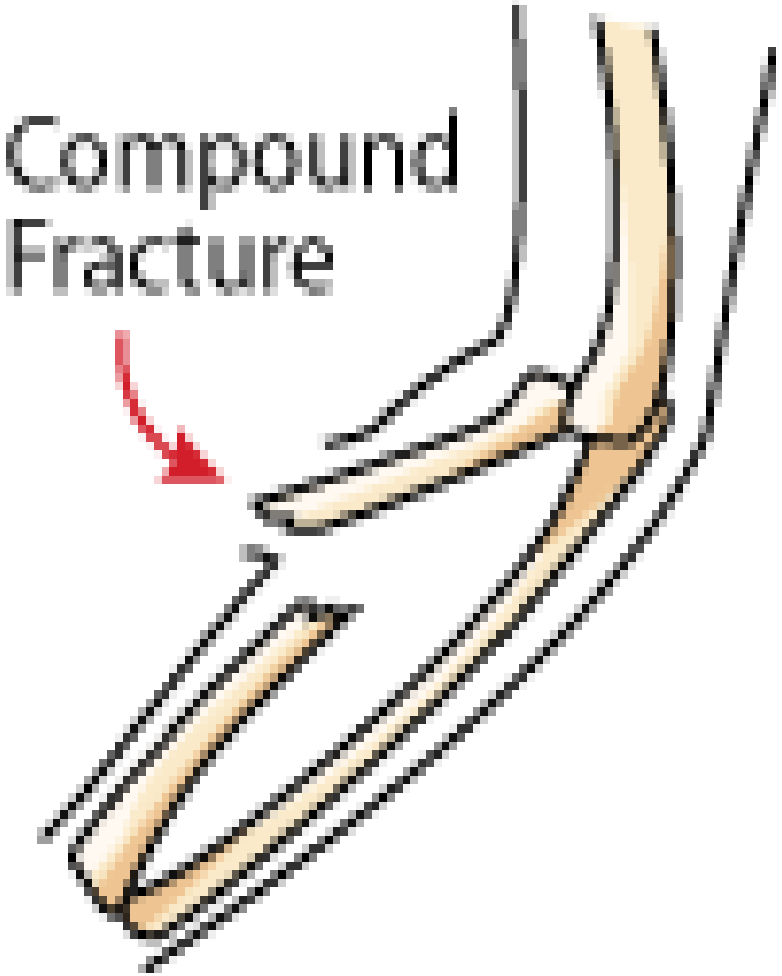

RISK FACTORS

1. Pathological fractures: osteoporosis, multiple myeloma, osteogenic sarcoma, metabolic diseases.
2. Trauma
3. Congenital conditions
4. Spontaneous

CLINICAL MANIFESTATIONS

1. Edema around the injured site.
2. Severe pain
3. Abnormal positioning of the extremity
4. Loss of normal function
5. False movement; movement occurs at the fracture site, bone should not move except at joints.
6. Crepitation: palpable or audible crunching as the ends of the bone rub together.
7. Discolouration of the skin around the affected area.
8. Sensation may be impaired if there is nerve damage.

DIAGNOSTICS

1. Clinical manifestations & history
2. X-ray film of involved area.

MANAGEMENT

1. IMMEDIATE IMMOBILIZATION
   - Suspected fracture area restricted from moving.

2. FRACTURE REDUCTION
   a) **Closed reduction:** nonsurgical, manual realignment of the bones, then injured extremity is placed in a cast for continued immobilization until healing occurs.
   b) **Open reduction:** surgical correction of alignment.

3. FIXATION DEVICES
   a) **External fixation-** application of a rigid external device consisting of pins placed through the bone & held in place by a metalic frame, requires meticulous care of pin insertion site.
   b) **Internal fixation** (ORIF open reduction, internal fixation): done through an open incision, & a hardware (pins, plates, rods, screws) is placed in the bone.
   c) Both methods

INTERNAL FIXATION DEVICES

Plate



Intra-
medullary
rod

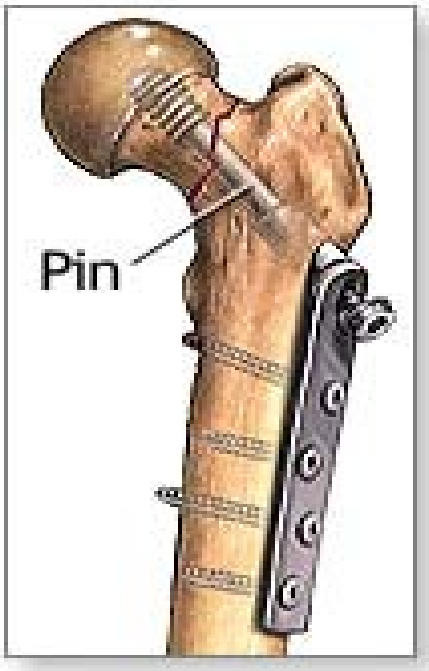

Pin

A.D.A.M.

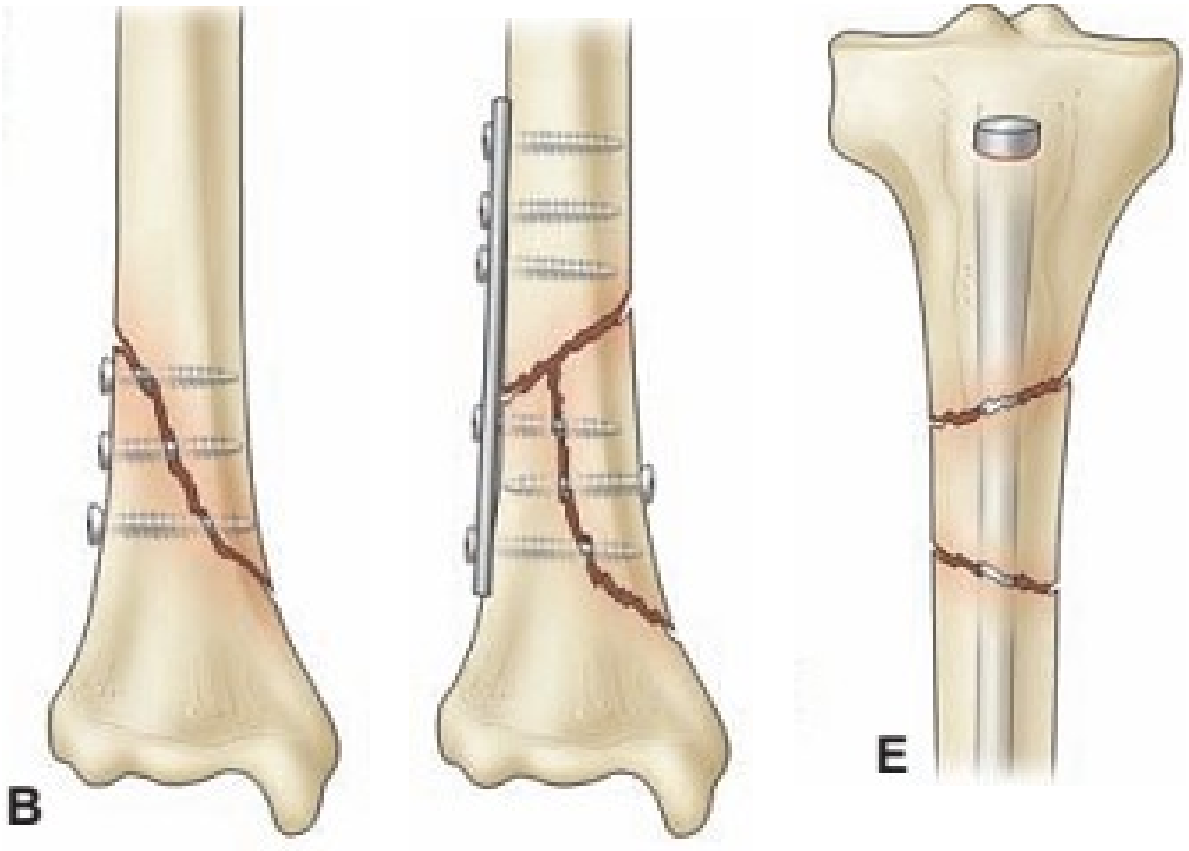

B, Screws:-oblique/spiral
D, Plate and six screws
E, Medullary nail.

EXTERNAL FIXATION DEVISES

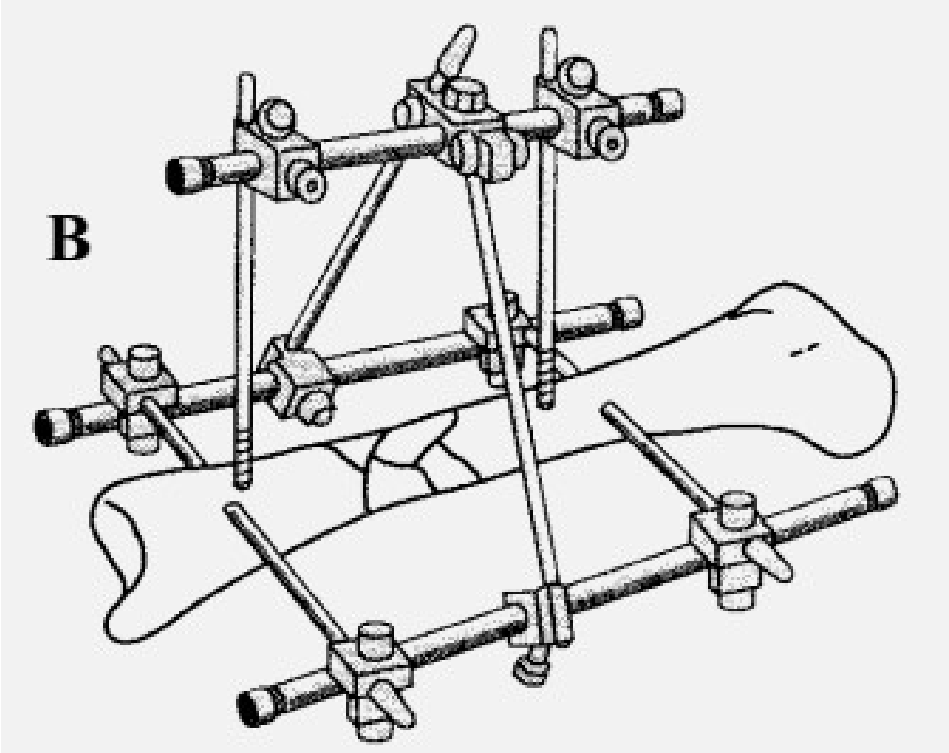

4. CAST APPLICATION

To maintain immobility of the injured area.

Type of cast applications

a) **Short arm cast:** extends from below the elbow to the palmar crease, secured around the base of the thumb. If the thumb is included, it is known as a *thumb spica or gauntlet* cast.

b) **Long-arm cast:** extends from the axillary fold to the palmer crease. The elbow usually is immobilized at a right angle.

c) **Long leg cast:** extends from the junction of the upper & middle third of the thigh base to the toes. The knee maybe slightly flexed

d) **Short-leg cast:** extends below the knee to the base of the toes. The foot is flexed at a right angle in a neutral position.

e) **Walking cast:** a short- or long- leg reinforced for strength.

f) **Body cast:** encircles the trunk.

g) **Shoulder spica cast:** a body jacket that encloses the trunk & the shoulder & elbow.

h) **Hip spica cast:** encloses the trunk & a lower extremity. A double hip spica cast includes both legs.

ARM CASTS

Short Arm Cast

Long Arm Cast

Arm Cylinder Cast

LEG CASTS

Short Leg Cast Leg Cylinder Cast Long Leg Cast

BODY CAST and HIP SPICA

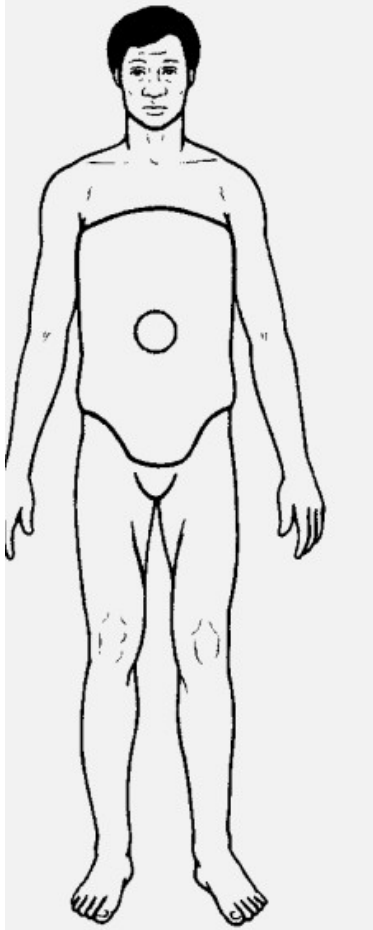

Body jacket cast

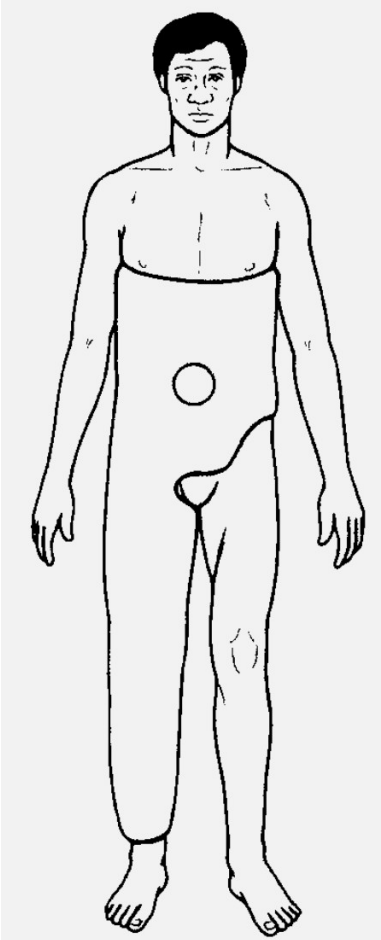

Single hip spica

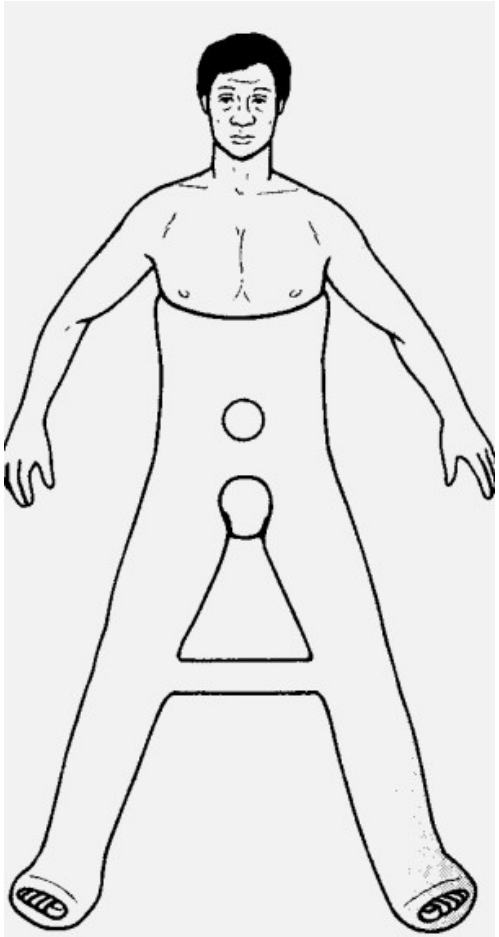

Double hip spica

5. SPLINTS

- Devises used to keep fractured bones, dislocated bones and broken bones immobile during the healing process.
- Splints can be used underneath casts or alone.
- Can be used for injuries of tissues attached to bones, such as muscles, ligaments or tendons.
- Occasionally, splints support joints afflicted with arthritis.
- Can be fashioned by using a stiff material as the foundation of the orthopedic splint and cloth, ropes or tape to hold the splint in place.

ARM SPLINT and THUMB SUPPORT SPLINT

RESTING ARM SPLINT and ARM SLING

LEG NIGHT SPLINT and KNEE BRACES

BACK SPLINT

ON CAST and TRACTION

6. TRACTION

- The application of a pulling force to an injured body part or extremity while a countertraction pulls in the opposite direction.

Purpose

1. Reduce, realign & promote healing of fractured bones
2. Decrease muscle spasms that may accompany fractures or follow surgical reduction .
3. Prevent soft tissue damage through immobilization
4. Treat deformities
5. Rest an inflamed, diseased, or painful joint.
6. Reduce & treat dislocations/subluxations
7. Prevent the development of contractures
8. Reduce muscle spasms associated with low back pain or cervical whiplash.
9. Expand a joint space during arthroscopy or prior to major joint reconstruction.

Types of Traction

a) **Skin traction:** application of a pulling force directly to the skin through the use of traction boot, traction
strip, halters, or belts.
For temporary use because of skin breakdown.

b) **Skeletal traction:** force applied directly to a metal pin (**Steinmann pin**) or wire (**Kirschner wire**) inserted through the bone. Sites include distal femur, proximal ulna.

Note: Traction could be static (continuous) or dynamic (intermittent).

SKELETAL TRACTION

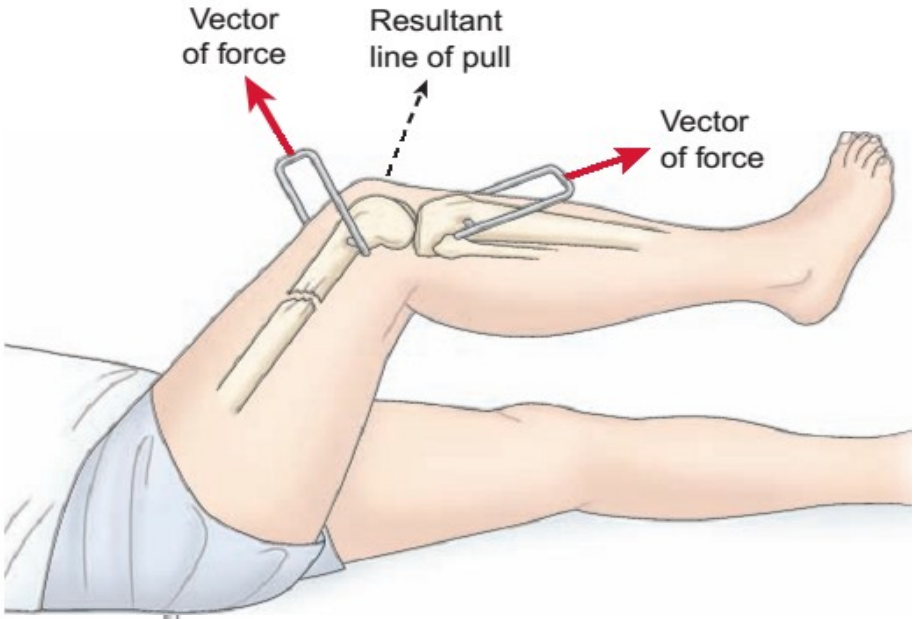

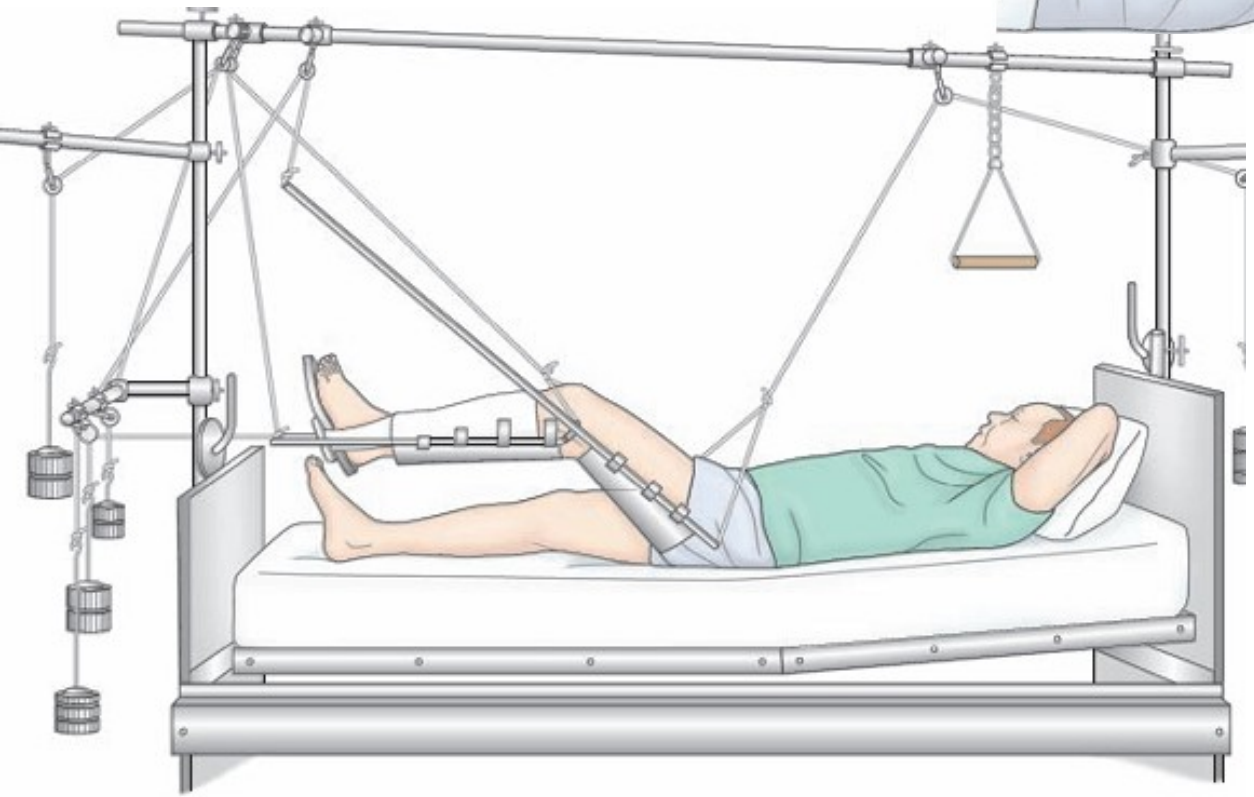

Balanced suspension skeletal traction with Thomas leg splint.

SKIN TRACTION

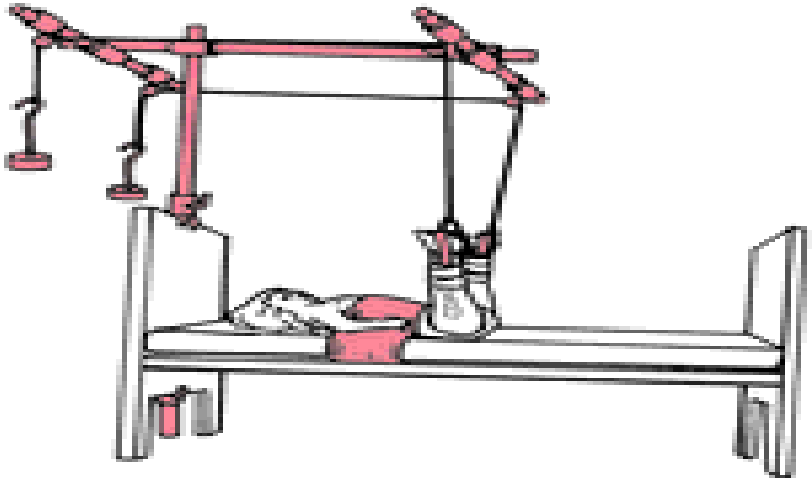

Bryant's traction

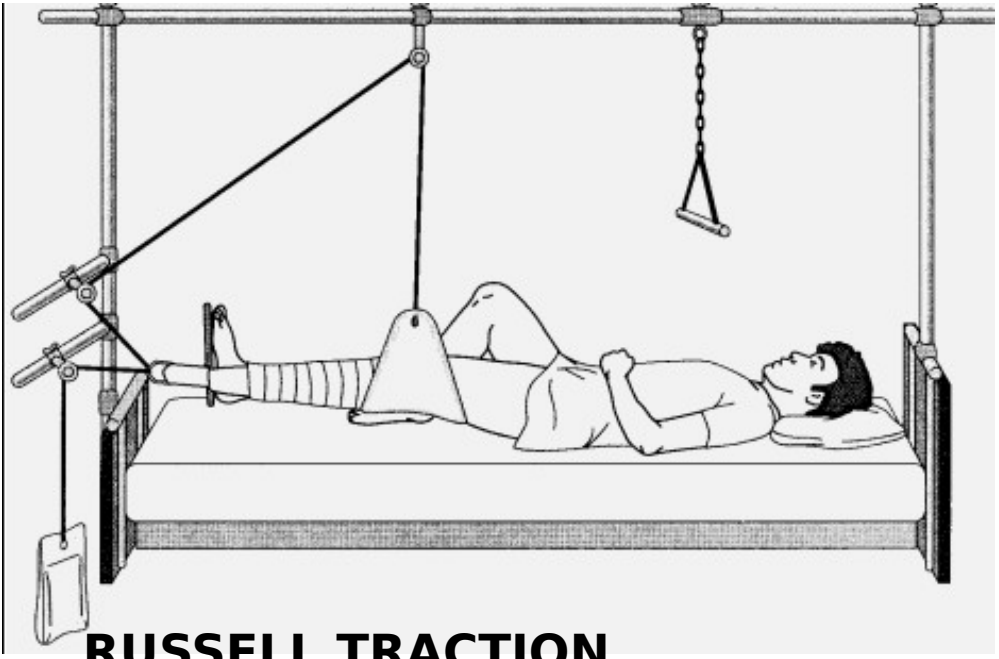

RUSSELL TRACTION (SKIN)

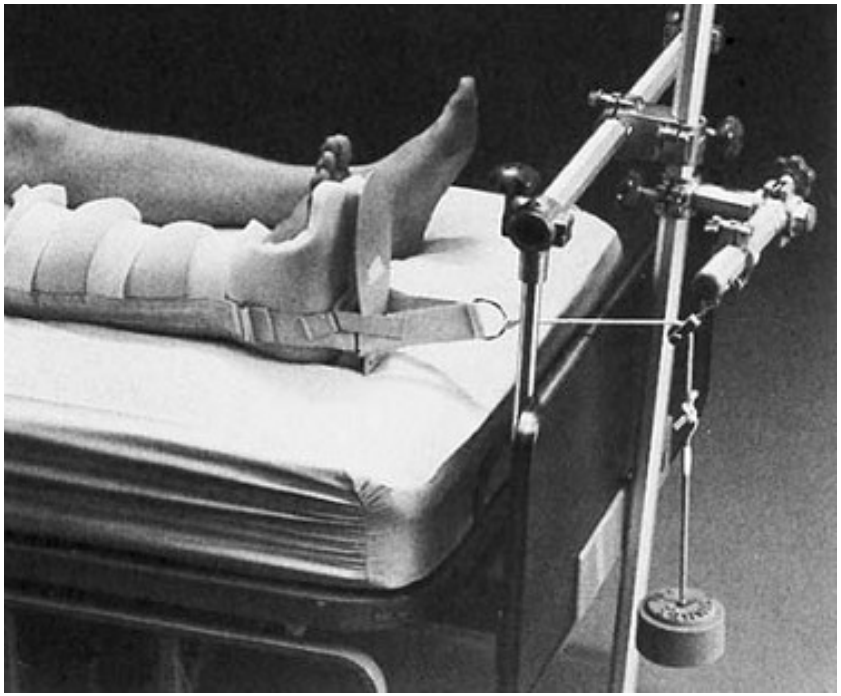

BUCK'S EXTENSION TRACTION (SKIN)

OTHER EXAMPLES

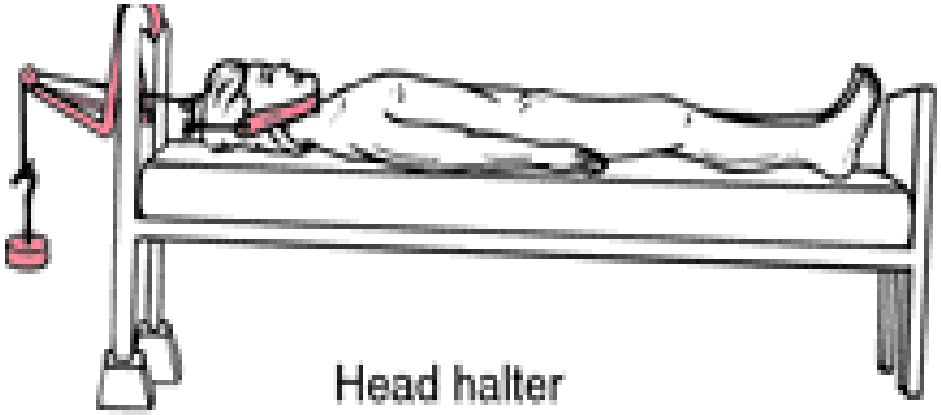

Head halter

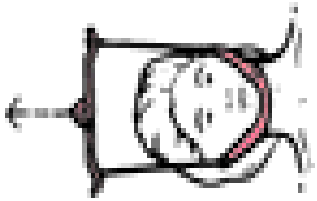

Top view

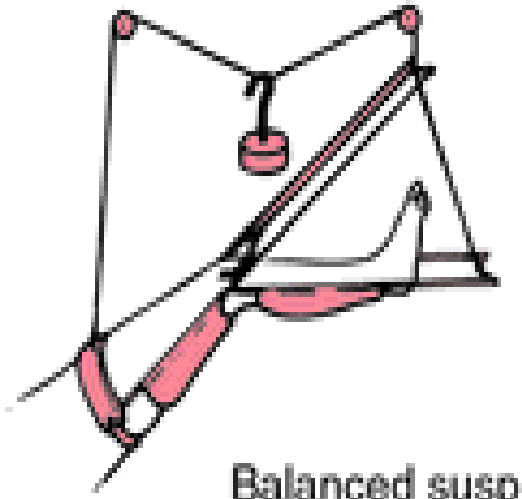

Balanced suspension

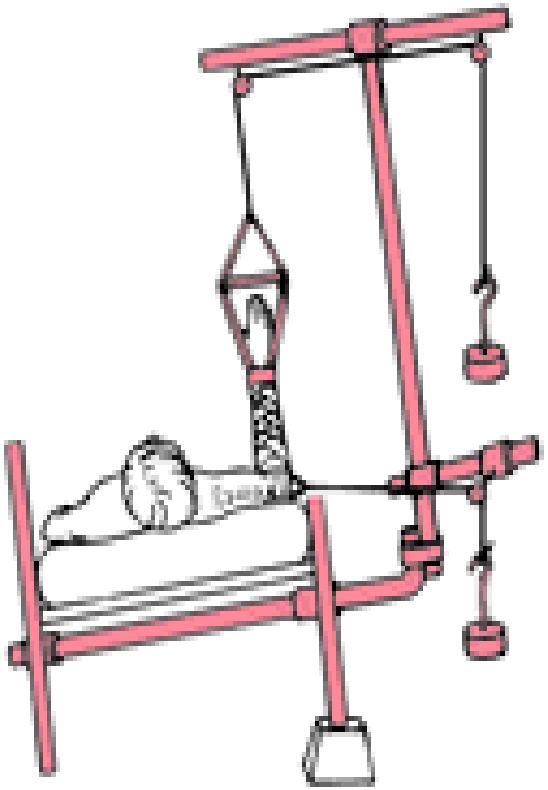

Lateral skeletal traction

NURSING MANAGEMENT

1. <u>Immobilize fractured extremity & provide emergency care before transporting victim.</u>

a) Evaluate circulation distal to injury

b) If pulses are not present or if the extremity must be realigned to apply splint for transfer, apply just enough traction to support & immobilize the fractured extremity in a position of the proper alignment.

c) Splint & immobilize extremity before transfer.

Note: traction to compound fractures may cause more damage.

d) Elevate the affected extremity, if possible, to decrease edema.

2. <u>Identify complications early</u>

Perform frequent peripheral nerve & vascular assessments distal to the area of injury or cast.

a) Impaired blood flow:

- pulselessness, pale skin & cool to touch, pain, swelling, edema distal to injury or cast, capillary refill >3 sec.

b) Compartment syndrome.

- Significant increase in pain not responding to analgesic.
- Loss of movement & sensation distal to cast.
- Skin is pale & cool to touch.
- Edema distal to injury or cast.
- Pulses may be present initially.
- Notify physician immediately.

c) Nerve damage from excess pressure.

- Paresthesia; numbness distal to injury or cast.
- Motor paralysis of previously functioning muscles.
- Feeling of deep pain & pressure.

d) Infection:

- May occur within the cast i.e unpleasant odor, purulent drainage, fever, & increased warmth over cast.

3. <u>Immobilize by cast (intermediate- Long-term).</u>

a) **Plaster cast:** allow cast to dry adequately before handling or moving the pt i.e

- Do not cover the cast with a blanket
- Encourage drying of casts using funs & maintaining adequate circulation.
- Avoid handling wet cast to prevent indentations in the cast, which may precipitate pressure areas inside the cast
- Reposition pt every 2 hrs to increase drying on all cast surfaces.
- “petaling” the cast is done to cover the rough edges & prevent crumbling of the plaster cast; edges are covered with small strips of waterproof adhesive
- Do not allow cast to become wet or excessively damp

Note: do not apply any form of heat to dry the cast.

b) **Synthetic casts** (fiberglass, polyester cotton knit) are lighter & require a minimal amount of drying time.

- Frequently used for upper body cast
- Preferable for infants or children.
- Cast does not crumble around the edges & does not soil as easily.
- Cast dries rapidly when it gets dump, & it does not disintergrate in water; some synthetic casts can be immersed for bathing.

c) **Body jacket cast & hip spica cast.**

- Evaluate abdominal discomfort caused by cast compression of mesenteric artery against duodenum.
- Relief of abdominal pressure can be achieved by means of NGT suction or cast removal & reapplication.
- Evaluate for pressure areas over iliac crest.

4. <u>Immobilization via traction.</u>

a) Assume that traction is continuous unless otherwise ordered.

b) Carefully assess for skin breakdown especially under the pt.

c) Do not change or remove traction weight on a pt with continuous traction.

d) The traction ropes & weights should hang free from any obstruction

e) Traction applied in one direction requires an equal counter-traction to be effective

f) Do not let the pt’s feet touch the edge of the bed, this will cause the counter traction to be lost.

g) Do not allow the traction weights to rest on anything

h) Carefully assess the pin sites (skeletal traction) for early recognition of complications e.g Osteomyelitis

Remember!!

PRINCIPLES OF TRACTION

1. Patient must be in correct body alignment at center of bed
2. Traction is maintained continuously, unless otherwise specified
3. Continuously maintain counter traction
4. All ropes must move freely on the pulley at all times
5. Rope knots should never touch the pulley
6. Ropes should be kept clear of bed linens/other objects
7. Weights must always hang freely
8. Skeletal traction must never be released

5. Prevent complications

5. From of immobility e.g venous stasis, thrombosis, pneumonia, contipation, UTI, decubitus ulcers, increased blood calcium leading to renal stones.
6. From internal or external fixation.

- Inspect exposed skin & pin sites for infection
- Cleanse around pin sites
- Perform wound care on incision area or area of trauma.
- Observe carefully for development of an infection
- Evaluate for circulatory & neurosensory impairment.

6. <u>Education</u>

a. Patient should not:

- Bear weight on the affected extremity until allowed
- Allow the cast to get wet.
- Insert anything under or in the cast
- Move or manipulate pins on an external fixator device.

b. Patient should:

- Assess pin sites for evidence of infection.
- Report symptoms associated with swelling or an increase in pain—unrelieved by analgesic.

SPECIFIC SITE FRACTURES

- RIBS
- HUMERAL NECK
- HUMERAL SHAFT
- PELVIS
- HIP
- FEMORAL SHAFT
- TIBIA-FIBULAR
- THORACOLUMBAR SPINE

FRACTURE RIBS

- Uncomplicated fractures heal 3 to 6 weeks without residue impairment
- Painful respirations cause pts breathing to be more shallow & coughing to be restrained, this precipitates building up of secretions & decreased ventilation.
- Multiple rib fractures may cause pnuemothorax.

FRACTURE RIBS

- Nurse assists the pt to splint chest while coughing & deep breathing to prevent pneumonia & atelectasis.
- Occasionally intercostal nerve blocks may be administered to relieve pain & permit productive coughing.
- Chest taping or strapping is not usually done because it decreases thoracic excursion.

FRACTURE HUMERAL NECK

- May occur through anatomical or the surgical neck of the humerus.
- Impact fractures common in the elderly after a fall.
- Are essentially nondisplaced fractures.
- Active middle aged pts may suffer severely displaced humeral neck fractures with associated rotator calf muscle damage.

MANAGEMENT FRACTURE HUMERAL NECK

1. Nondisplaced fracture is supported & immobilized by a sling & swathe that secure the supported arm to the trunk.

2. Require 6-10 wks to heal & pt should avoid vigorous activity for another 4 wks.

   Residual stiffness, aching & some limitation of ROM may persist for 6 or more months.

3. Displaced humeral neck fracture may need closed reduction, ORIF, or humeral head prosthesis.

4. Limitation of motion & stiffness of the shoulder occur from disuse.
   - Pendulum or circumduction exercises are done after period of immobilization (Pt. leans forward & allows affected arm to abduct & rotate).

FRACTURE HUMERAL SHAFT

Frequently caused by:

a) Direct trauma resulting in transverse, oblique or comminuted fracture.

b) Indirect twisting force that results in a spiral fracture. The nerves & brachial blood vessels may be injured with these fractures. Wrist drop indicates radial nerve injury.

MANAGEMENT

1. Hanging cast

Provides traction to the arm when the pt is upright hence reducing & immobilizing the fracture.

- Must be independent (free from support)
- Sleep in upright position so that traction is maintained.
- Watch out for complication—non-union.
- Finger & pendulum shoulder exercise start as soon as possible
- Need 10 weeks to heal with hanging cast.
- After cast removal, a sling is applied & exercise of wrist, elbow, & shoulder started.

2. Functional bracing.

A contoured thermoplastic sleeve is secured in place with interlocking fabric closures around the upper arm immobilizing the reduced fracture.

3. Shoulder spica cast: may be used during early treatment of unstable humerus fracture.
4. Skeletal traction: may be used for pts who must remain in bed because of their injuries.
5. Open fractures are treated by external fixators.
6. ORIF is necessary with nerve palsy or pathologic fractures

FRACTURE PELVIS

The sacrum, ilium, pubis, & ischium bones form the pelvic bone, a fused, stable, bony ring in adults.

PELVIC BONES

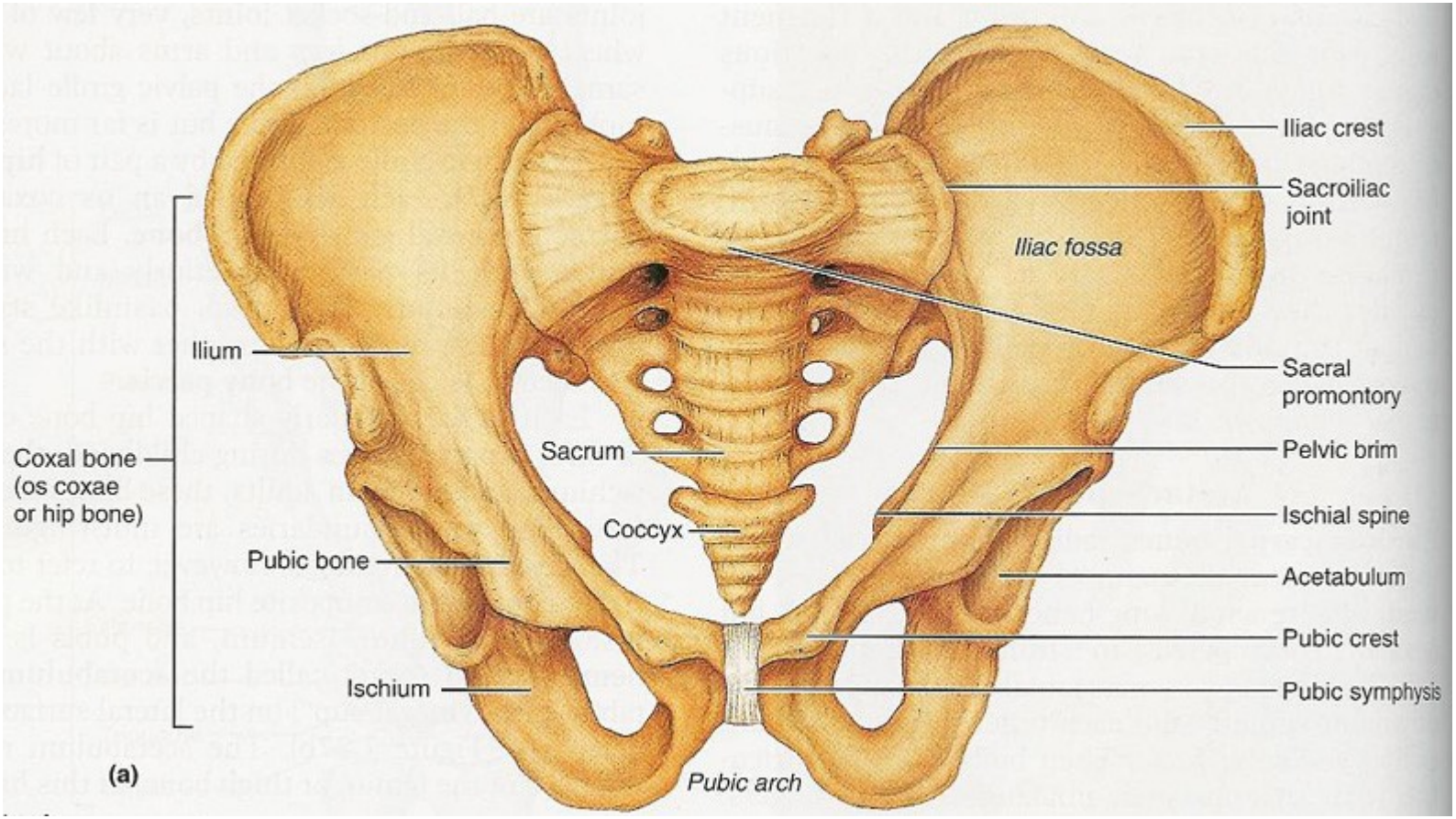

CAUSES OF PELVIC FRACTURE

- Falls, crush injuries
- At least $^{2}/_{3}$ are associated with multiple injuries.
- High mortality rate associated with hemorrhage, pulmonary complications, fat emboli, intravascular coagulation, thromboembolic complications, & infection.

MANIFESTATIONS OF PELVIC FRACTURE

- Ecchymosis
- Tenderness over the symphysis pubis, anterior iliac spine, iliac crest, sacrum or coccyx.
- Local swelling
- Numbness or tingling of pubis, genitalia, & proximal thighs.
- Inability to bear weight without discomfort.

TYPES OF PELVIC FRACTURES

1. **Stable pelvic fractures**

- May include fractures of a single pubic or ischial ramus; ipsilateral pubic & ischial rami; pelvic wing of ilium (Duverney's fracture); or fracture of the sacrum or coccyx.
- Treated with a few days of bed rest & symptom management until the pain & discomfort are controlled.
- Most heal rapidly because the hip is made up mostly of cancellous bone, with rich blood supply.
- Ambulation is resumed using ambulatory aids for protected weight bearing.

2. Unstable pelvic fractures

May be any of three (3) types

i. Rotationally unstable: from lateral or AP compression. e.g. open book type (separation at the symphysis pubis)

ii. Vertically unstable e.g. vertical shear type (superior-inferior displacement of the pelvic sides).

ii. A combination of both.

Treatment: External fixation or ORIF

3. **Vertical shear pelvic fractures**

- Involves the anterior & posterior pelvic ring with vertical displacement, usually through the sacro-iliac joint with disruption of ligaments.
- Management: External fixation with or without skeletal traction & ORIF.

4. **Fracture acetabulum**

- Often seen after motor vehicle crashes in which the femur is jammed into the dashboard.
- Management: depends on the pattern of fractures; (traction, open reduction, orthoplasty).

DIAGNOSIS

a) Clinical manifestations
b) X-ray
c) CT-scan: sacroiliac joint disruption, soft tissue trauma, hematoma, & fractures.

MANAGEMENT

1. Check for possible hemorrhage from torn iliac artery & shock occurance- palpate pulses.
2. Peritoneal lavage may be done to detect intra-abdominal hemorrhage.
3. Assess for injuries to the bladder, rectum, intestines, other abdominal organs, & pelvic vessels & nerves.
4. Assess injury to urinary tract by urinalysis.

5. Avoid urethral catheter till status of the urethra is known.
6. Exercises (ROM, & strengthening), elastic stockings & elevation of the foot of the bed to aid venous return and diminish the effects of bed rest.
7. Pt. may be mobilized with progressive weight bearing, usually with crutches.

LONGTERM COMPLICATIONS

1. Malunion
2. Nonunion
3. Residual gait disturbances
4. Back pain from ligament injury

FRACTURE HIP

RISK FACTORS (COMMOBIDITIES)

1. Osteoporosis especially in elderly women.
2. Weak quadriceps muscles also age related
3. Conditions that produce decreased cerebral arterial perfusion (TIA, anemia, emboli, cardiovascular disease, effects of medications).

All attribute to incidence of falls in elderly people.

There are two (2) types of hip fractures.

a) ***Intracapsular fractures:*** head and neck of the femur.

May damage the vascular system denying nutrient supply & bone may die

Nonunion or aseptic necrosis is

b) ***Extracapsular fractures:*** trochanteric region & subtrochanteric region.

Have an excellent blood
y & heal readily.

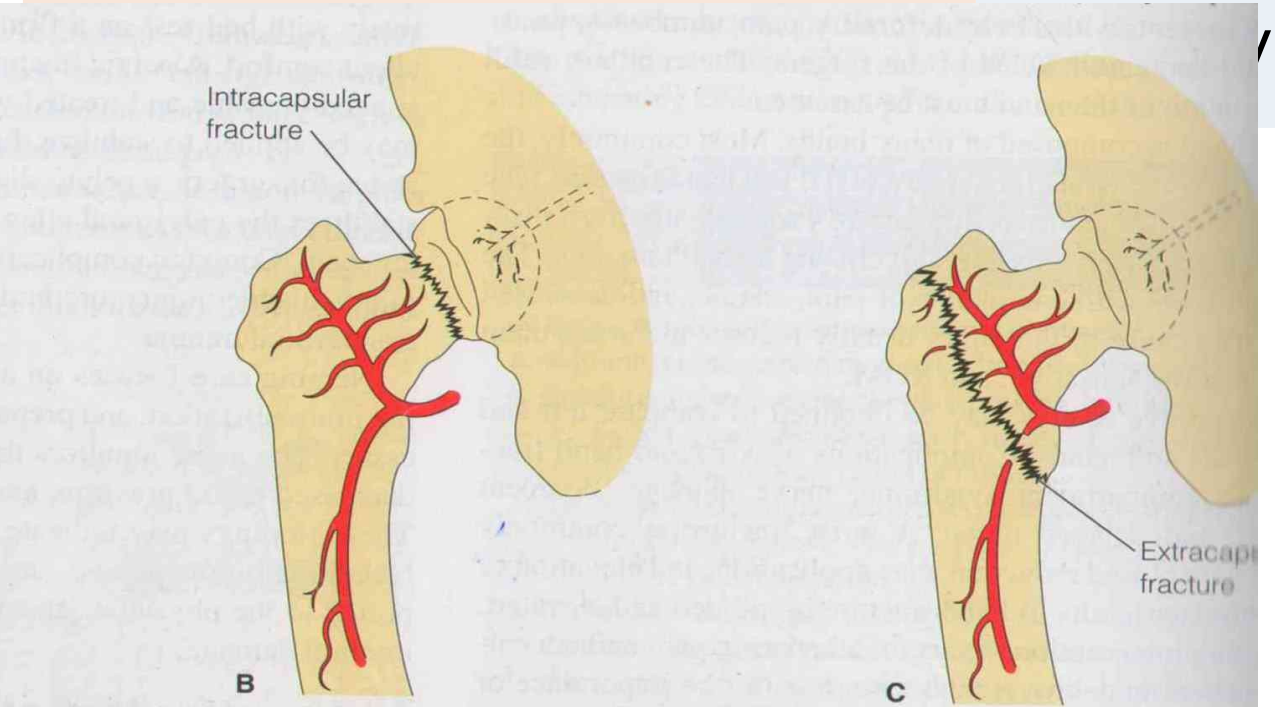

CLINICAL MANIFESTATION

1. **With fractures of the femoral neck**: leg is shortened, adducted, & externally rotated. Pt most comfortable with leg slightly flexed in external rotation.

2. **Impacted femoral neck fractures**: moderate discomfort even on movement, may allow Pt. to bear weight, no obvious shortening or rotational changes.

3. **Extracapsular femoral fractures**: significantly shortened extremity, greater external rotation, muscle spasms, large hematoma or ecchymosis.

DIAGNOSIS

X-ray.

CT scan

MEDICAL MANAGEMENT

1. Temporary skin traction (Buck’s extension)
2. ORIF
3. Replacement of the femoral head with a prosthesis (hemiarthroplasty).

HIP REPLACEMENT/ FEMORAL-HEAD PROSTHESIS

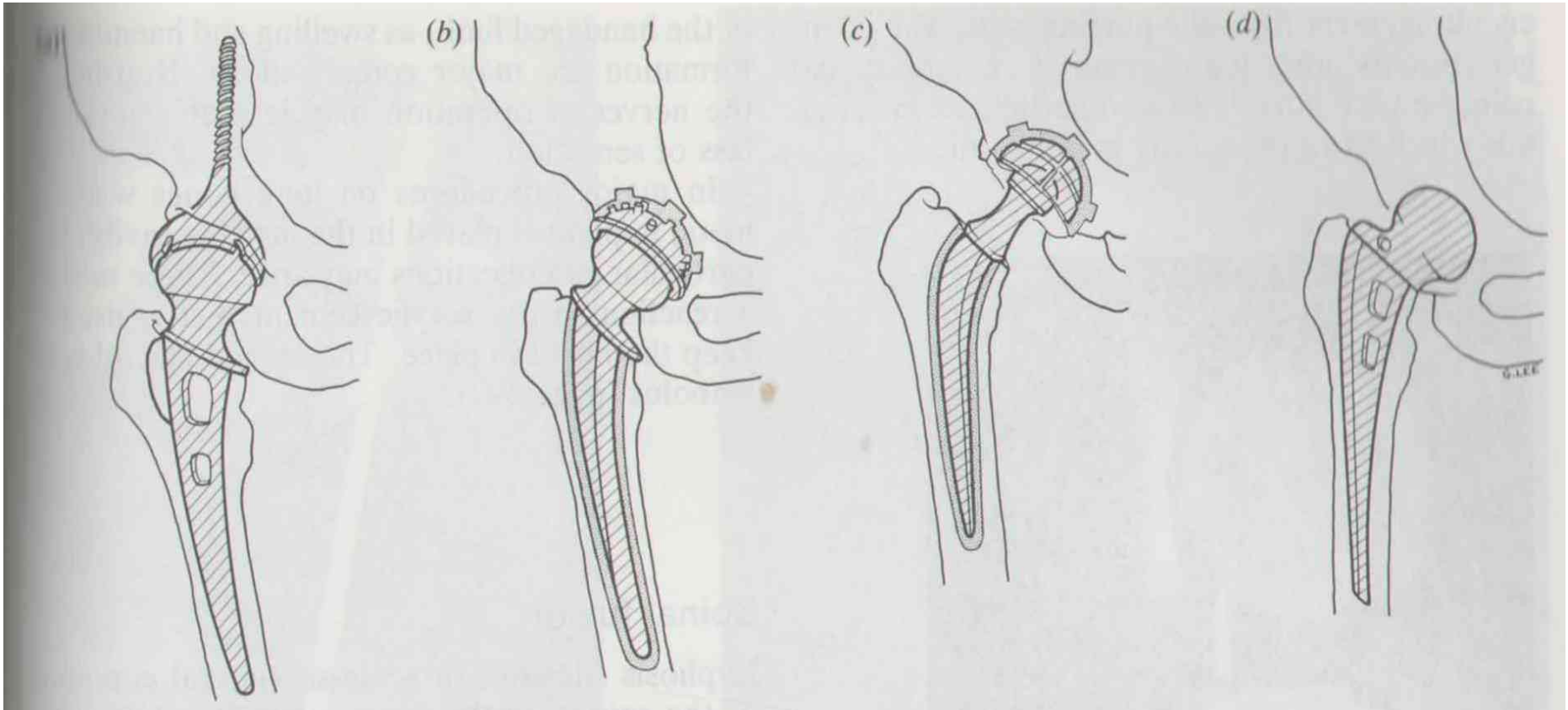

(*a*) **Ring.** Metal to metal; no cement; short neck; lag screw up into ilium taking vertical stress.

(*b*) **McKee–Farrar.** Metal to metal; cup carries studs which lock it into the reamed-out acetabulum; bone cement to shaft.

(*c*) **Charnley.** Metal to plastic; small head with low friction polypropylene cup.

(*d*) **Austin Moore.** Metal to bone; the acetabulum is reamed out to take a large head.

POST-OP NURSING CARE

1. Like all pts undergoing orthopedic surgery.
2. 1st 24-48 hrs, relieving pain & preventing complications are priorities.
3. Deep breathing, coughing (incentive spirometry) & foot flexion exercises every 1-2 hrs.
4. Prophylactic antibiotics, analgesics, anticoagulants

5. Home modification e.g putting a toilet raiser on the toilet sit, use walker, sleep down-stairs.
6. Thigh high elastic compression stockings.
7. A pillow between legs to maintain abduction & alignment even when turning.
8. Progressive assisted walking as indicated by therapist.

SELF-CARE AFTER FEMORAL-HEAD PROSTHESIS

Do Not

- Force hip into greater than 90 degrees of flexion*
- Force hip into adduction
- Force hip into internal rotation
- Cross legs
- Put on own shoes or stockings until 8 wk after surgery without adaptive device (e.g., long-handled shoehorn or stocking-helper)
- Sit on chairs without arms to aid rising to a standing position*

Do

- Use toilet elevator on toilet seat•
- Place chair inside shower or tub and remain seated while washing
- Use pillow between legs for first 8 wk after surgery when lying on "good" side or when supine*
- Keep hip in neutral, straight position when sitting, walking, or lying*
- Notify surgeon if severe pain, deformity, or loss of function occurs*
- Inform dentist of presence of prosthesis before dental work so that prophylactic antibiotics can be given

COMPLICATIONS

1. Neurovascular complications
   a) Direct injury to nerves & blood vessels or tissues (pressure).
   b) DVT
2. Pulmonary complications: pneumonia
3. Skin breakdown: blisters from tape, pressure ulcer.
4. Infection
5. Nonunion
6. Avascular necrosis
7. Fixation device problem (protrusion of the fixation device through the acetabulum; loosening of hardware.

FRACTURE HIP

Total Hip Replacement

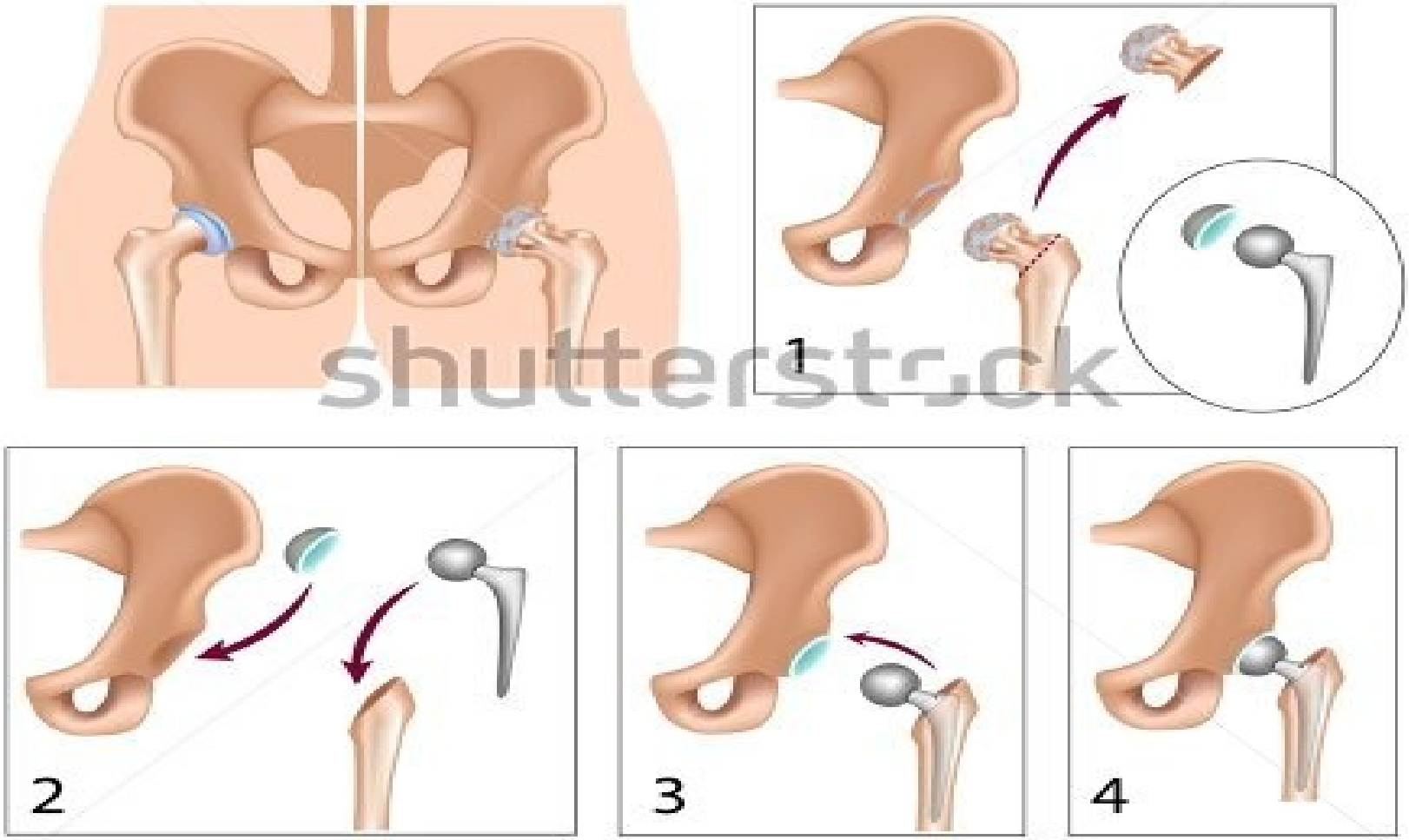

shutterstock

www.shutterstock.com · 94626565

FRACTURE FEMURAL SHAFT

- Great force is required in adults for this fracture to occur.
- May be transverse, oblique, spiral or comminuted.
- Massive blood loss common leading to shock.

SIGNS AND SYMPTOMS

1. Enlarged, deformed, painful thigh.
2. Can not move hip or knee.

ASSESSMENT & DIAGNOSIS

1. Neurovascular status check
2. Doppler ultrasound to assess blood flow
3. X-rays: associated dislocation of the hip & knee.

MANAGEMENT

1. Neurovascular monitoring.
2. Skin traction for comfort & immobilization of the fracture to minimize soft tissue injury.
3. Generally, skeletal traction for muscle relaxation & alignment of the fracture fragments before ORIF.
4. In ORIF: intramedullary nailing devices, interlocking nail, or compression plate & screws provide adequate internal fixation.

5. Active muscle movement enhances healing.
6. Fractures of the middle & distal shaft (supracondylar). May be managed with skeletal traction after 2-4 weeks.
7. When pain & swelling have subsided skeletal traction is removed & a cast brace placed

Complication: Restriction of knee motion due to lack of early exercise.

FRACTURE TIBIA & FIBULA

- Results from a direct blow, falls with foot in a flexed position or a violent twisting.
- Usually occur in association with each other.

ASSESSMENT & DIAGNOSTIC FINDINGS

1. Assess nerve damage: inability to dorsiflex great toe with diminished sensation in the first web space.
2. Tibial artery damage: assess skin colour, temperature & capillary refill.
3. Monitor anterior compartment syndrome: pain unrelieved by analgesics & increasing with plantar flexion, & paresthesia.

MANAGEMENT

1. Pins-in-plaster technique.
2. Closed tibial fractures: closed reduction in long leg-walking or patellar-tendon-bearing cast.
3. Partial weight bearing after 7-10 days.
4. Cast changed to short leg cast or brace in 3-4 wks to allow knee motion.
5. Healing takes 6-10 wks.
6. Comminuted fractures may need skeletal traction or fixation (internal/external).
7. Continue neurovascular assessment and limb elevation.

FRACTURE THORACOLUMBAR SPINE

May involve

1. Vertebral body
2. Lamina & articulating process
3. Spinous process or transverse processes

- T_{12} – L_2 are most vulnerable to fractures.
- Generally due to indirect trauma caused by excessive loading, sudden muscle contraction, or excessive motion beyond physiologic limits.
- Osteoporosis contributes to vertebral body collapse.

SIGNS & SYMPTOMS

- Acute tenderness
- Swelling
- Paravertebral muscle spasm
- Change in normal curves or gaps btn. spinous processes.

Note: Immobilization is essential till initial determination of spinal cord injury & fracture stability.

FRACTURE THORACOLUMBAR SPINE

- Stable fractures are due to flexion, extension, lateral bending, or vertical loading.
- Few spinal fractures are associated neurologic deficit which require immediate surgery (laminectomy with spinal fusion) to decompress the spinal cord
- Unstable fractures occur with fracture dislocation & exhibit disruption of both anterior & posterior structural columns. The potential for neural damage exists.

MED-SURG MANAGEMENT

1. Stable: conservative mgt. with limited bedrest, with the head of bed <30^0, till acute pain subsides
2. Pain management; Analgesics
3. Assess for paralytic ilius because of associated retroperitoneal haemorrhage
4. Begin ambulation early slowly
5. Avoid having Pt. bend, stoop, twist, sit, or lift.

5. A spinal brace or thoracolumbar orthosis may be applied for support during progressive ambulation & resumption of activities.
6. Weigh reduction
7. With unstable fracture, maintain bed rest with special turning device (eg stryker frame) to maintain spinal alignment.
8. Neurological observation
9. Unstable fractures: open reduction, decompression & fixation with spinal fusion & instrument stabilization.

PRE-OPERATIVE NURSING CARE

1. Perform pre-op general nursing care
2. Practice log rolling & voiding from supine position.
3. Discuss post-op pain & methods to decrease pain.
4. Evaluate specific pain characteristics for post-op reference.
5. Evaluate bowel & bladder function.
6. Establish a baseline neurological assessment for post-op reference.

POST-OP CARE (LAMINECTOMY) *Laminectomy:* surgical removal of the herniated portion of the disk.

1. Keep the bed in a flat position.
2. Log rolling pt when turning
3. Keep pillows between the legs when client is positioned on the side.
4. Pt post microlaminectomy has fewer mobility, often they may assume a position of comfort.
5. Maintain homeostasis & assess for complications post laminectomy.
   a. Assess incision area for leakage of CSF & bleeding.
   b. Analgesic via PCA pump or epidural catheter
6. Start mobilization with assistance of physiotherapist